-Anatomy-

-R.M. Anderson-

March 21, 1905. Dr. Lord

The Pelvis.

Pelvic Girdle - comparable to shoulder girdle, but forms a complete ring. Heavier and firmer, to support weight of body.

Pelvis { 2 Ossa Innominata - united in front by symphysis pubis
1 Sacrum - unites innominate bones behind

Os innominatum - shapeless; somewhat resembling a figure 8. slightly twisted upon itself.

Made up by union of three bones:-

Ilium }
Ischium } separate in embryonic state, but later fuse
Pubis } into one firm solid bone.

These three bones come together in the acetabulum or cotyloid cavity.

The pelvis is tilted forward so that the acetabulum comes directly above the tuberosity of the ischium

Dr. Prentiss.

Abdominal Muscles –

Innominate bone – figure 8-shaped
made of 3 bones

Ilium – 4 borders

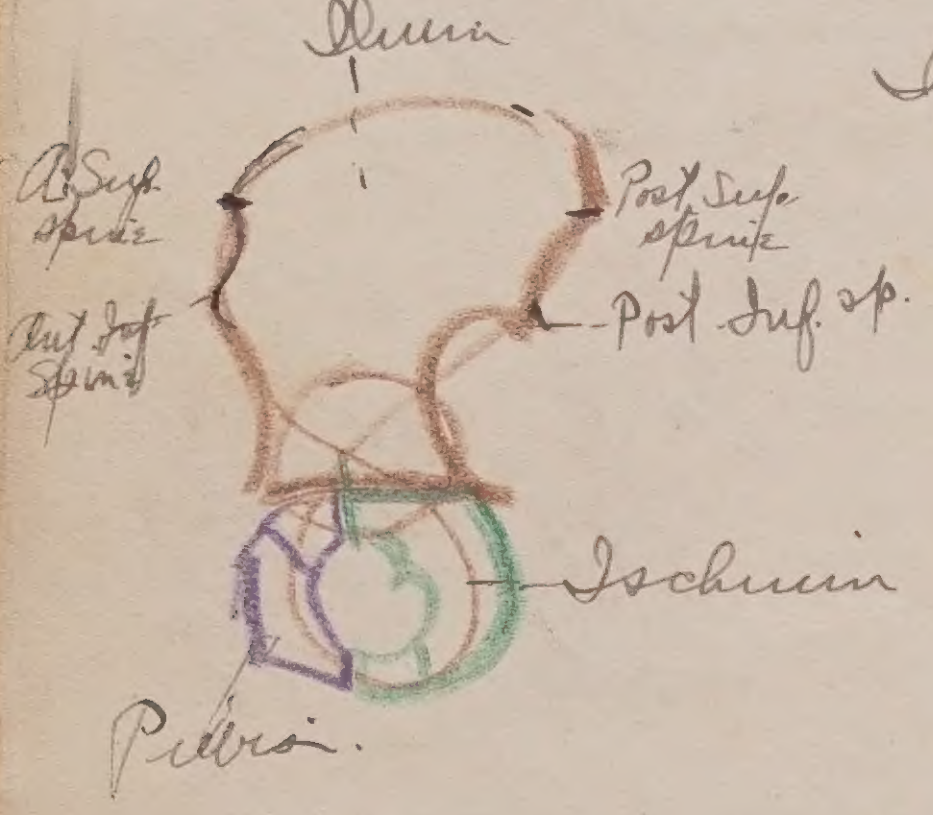

Ischium –
- Body – includes the acetabulum
- Head
- Neck
- Tuberosity
- Ascending Ramus

Pubis –
- Body
- Ascending (Horizontal) Ramus



Ilium –
Crest has 3 lips

1/2 Exterior – 1/2 inserted External Oblique Muscle

Intermediary portion 2/3 Arises Internal Oblique;

3/4 Arises Transversalis

Outer lip Posterior 1/2 arises Latissimus dorsi

Quadratus lumborum
Erector spinae

From posterior 1/4 of inner lip arises Quadratus lumborum and Erector spinae

Serratus magnus - from 8 Upper Ribs

Latissimus dorsi - from 4 lower ribs

External Oblique - from 8 lower ribs - interdigitating with serratus magnus and latissimus dorsi.

Anterior Oblique - Meet to form Linea Alba.

Poupart's Ligament } Extends - from Ant. Sup. spine of ilium to spine of pubes -

2 Rectus abdominales - Straight Muscles of abdomen = underneath rectus abdominalis.
Nerve supply - lower intercostals.

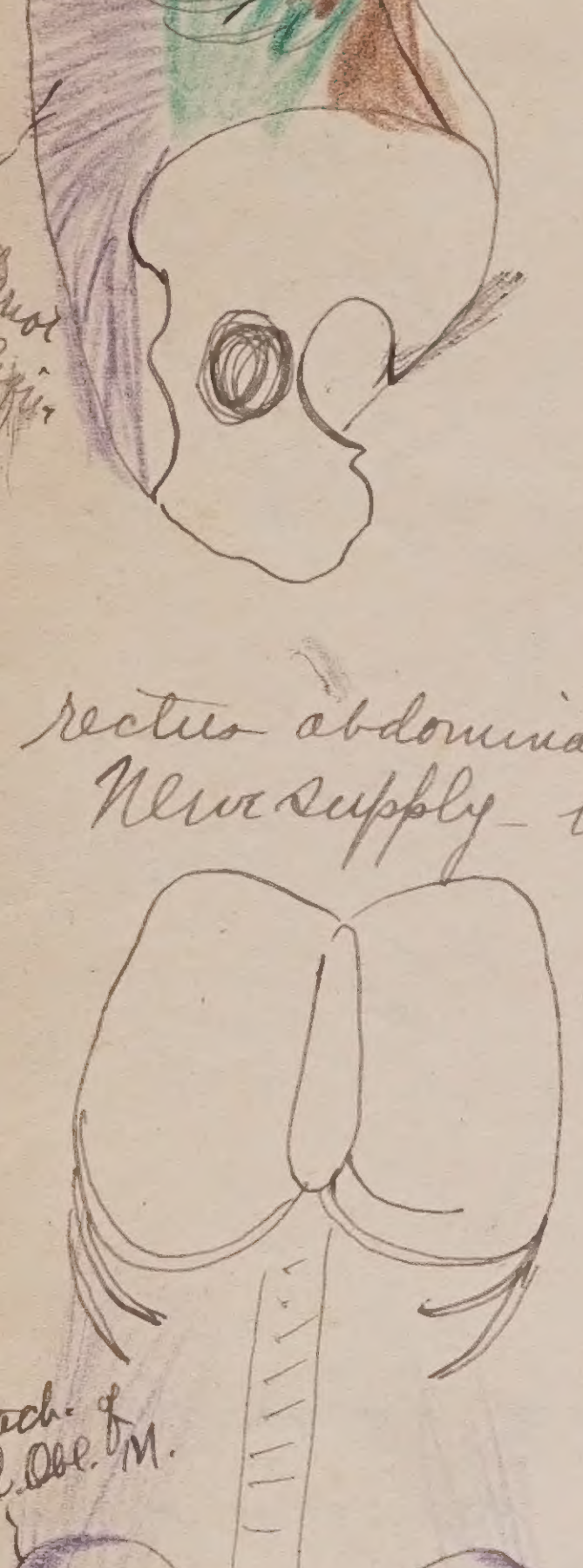

Poupart's ligament
lower edge of Ext. Oblique M.
Int. Obliquus - arises from Poupart's Lig.; ant. $\frac{2}{3}$ Crest of Ilium, inserted into 6 lower ribs, and aponeu. Fibre run upwards and forward (inward)

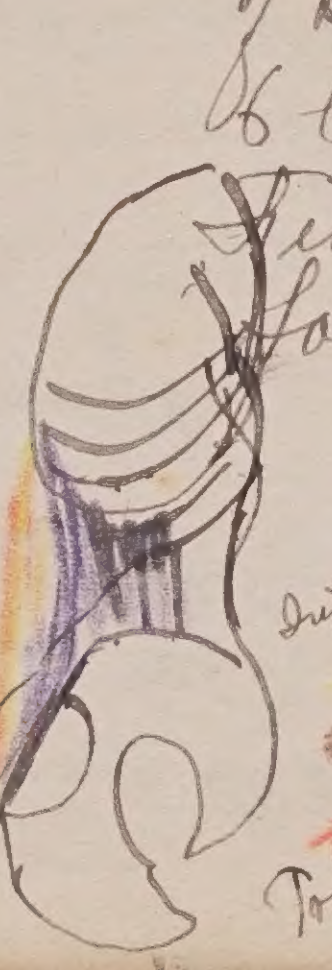



Conjoined tendon - inserted into crest of pubis
In upper portion 2 layers (aponeurosis of Ext. Oblique and Int. Oblique)
pass over Rectus abdominalis - and 2 layers behind. Internal Oblique and Transversalis.
In lower one-fourth - 4 layers are all in front. - Semi-lunar fold of Douglas

These muscles serve to press down abdomen, compressing bladder, rectum, uterus.

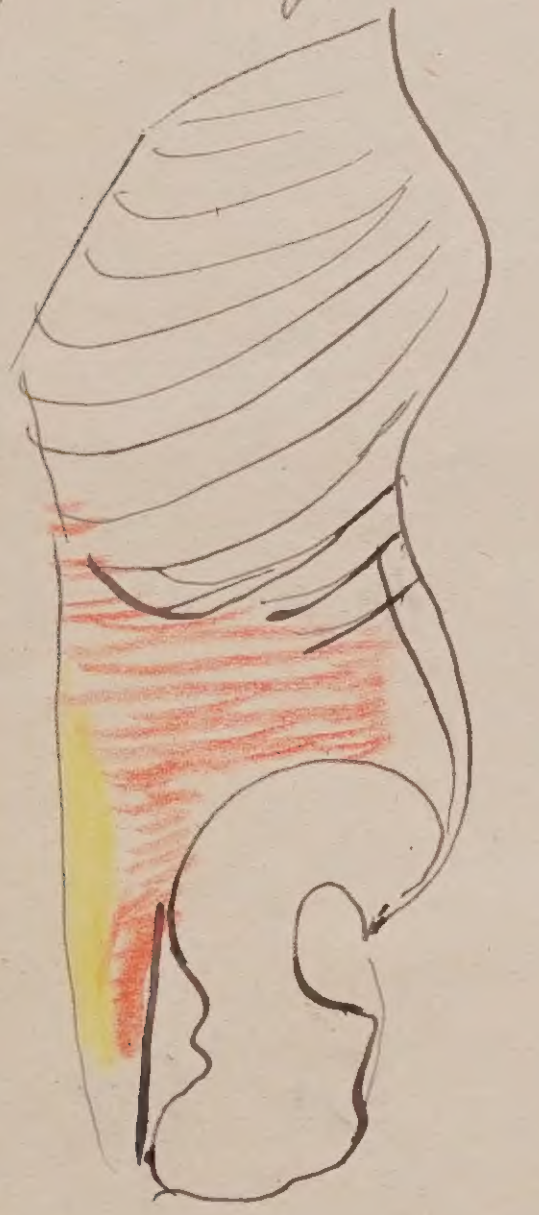

Transversalis Muscle - fibres arise from post. port. Poupart's ligament
ant. 2/3 Crest of Ilium
Crosses horizontally to meet fellow of opposite side

Ext. Obl. - fibres go downward.
Int. Obl. - Upwards
Transversalis - transversely

Nerve-supply is also from { Ilio-hypogastric
Ilio inguinal

Descent of testicles from abdominal cavity into scrotum, forms External ring by pushing out aponeurosis of Transversalis

Arched fibres of Transversalis and Int. Obl. come together - as conjoined tendon.

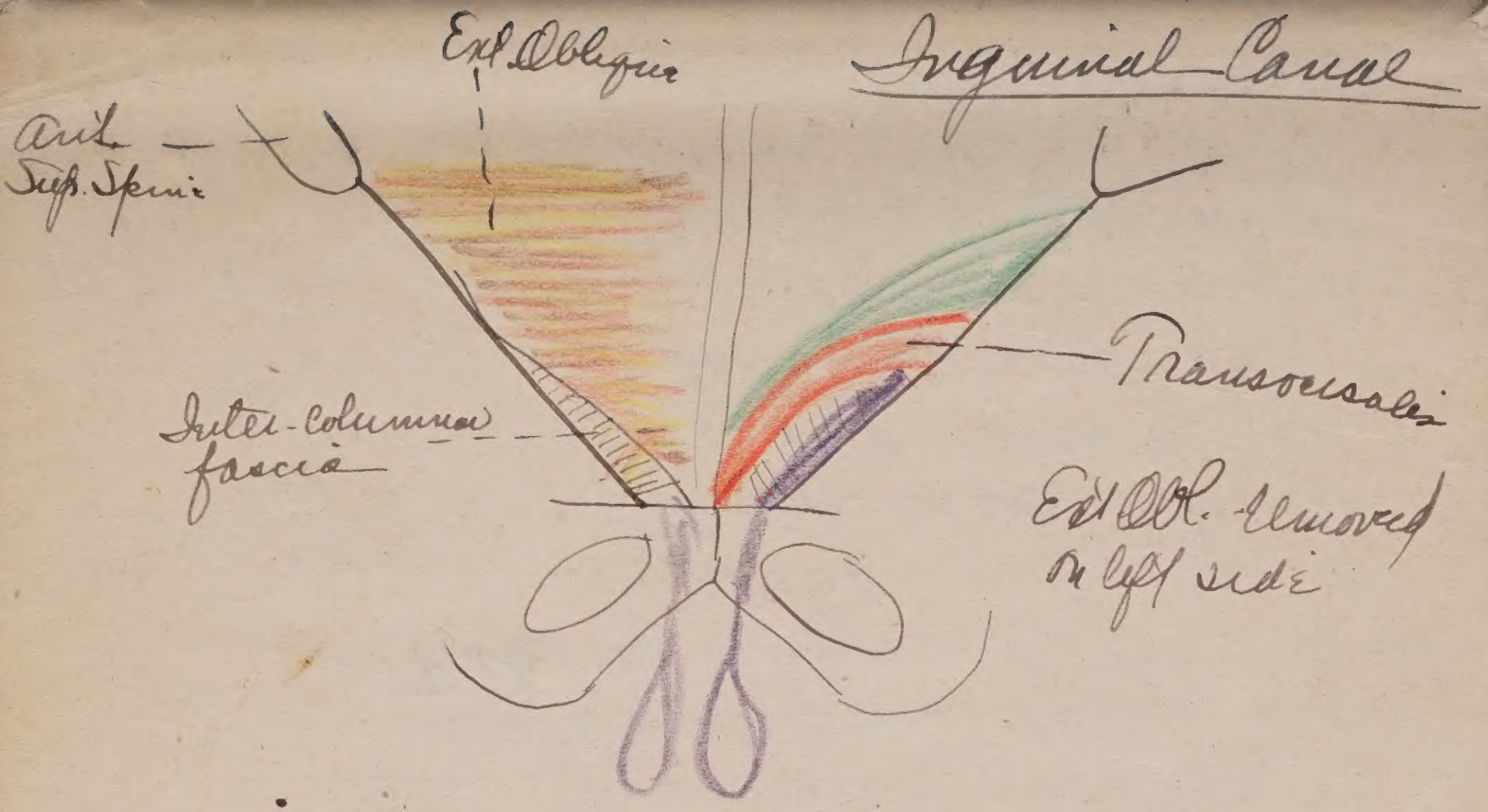

Diameters of Pelvis

Antero-posterior - from symp-pub. to sacral promontory.

Transverse -

Oblique - - from artic. of sacrum & ilium to ileo-pectineal eminence on opposite side (the most important - longest).

Diameters of Outlet of Pelvis.

Top of pubic Arch
Coccyx
Tuberosity to tuberosity

Antero-posterior -
Transverse -

Ilium –

(16 muscles attached)

2 Surfaces –

External Surface (Dorsum)

Superior Curved line
Middle " "
Inferior " "

#

Muscles {
Gluteus maximus
Gluteus medius
Gluteus minimus
Reflected tendon of Rectus.
(Pyriformis, to upper part of Gr. Sacro-sciatic Notch.)

(Forms little less than 2/5 of acetabulum)

Internal surface –

Iliac fossa (venter ilii).
{ Iliacus muscle
(nutrient canal).

Linea Ilio-pectinea –
{ Obturator internus
Erector and Multifidus Spinae.

Crest –

Anterior superior spinous process
~~Post~~ Anterior inferior " "

External lip.
{ Tensor fasciae femoris
Obliquus externus abdominis
Latissimus dorsi
fascia lata along whole l.

Intermediary space.
{ Internal Oblique

Internal lip -
- Transversalis muscle
- Quadratus lumborum
- Erector spinae
- Iliacus
- Fascia iliaca

Anterior Border

Anterior superior spinous process.
- Fascia lata } to outer border.
- Tensor fascia femoris }
- Iliacus - inner border.
- Sartorius } to extremity.
- Pouparts ligament }

Anterior inferior spinous process.
- Straight tendon Rectus femoris.
- Ilio-femoral ligament

Ilio-psoas M. passes over inner side.

Ilio pectineal Eminence - marks union of ilium and os pubis

Posterior Border -

Posterior superior spinous process
- Sacro-iliac ligaments
- Multifidus spinae

Posterior inferior spinous process

Ischium — (13 Muscles attached).

Body — somewhat triangular

3 surfaces —

External surface — little more than 2/5 of acetabulum.
Cotyloid fibro-cartilage.

Internal surface — lateral boundary of true pelvic cavity.
{ Obturator internus

Posterior surface — quadrilateral form groove below — for tendon of Obturator externus M.
{ Gemellus inferior
~~Gemellus superior~~

3 Borders —

External — rim of acetabulum
Internal — outer circum. Obtur. foramen.
Posterior border —

Spine of Ischium —
{ Gemellus superior (Externally
Coccygeus } internally
Levator ani }
Lesser Sacro-sciatic Lig

Great Sacro-sciatic notch transmits Pyriformis M., gluteal vessels, Sup. and inf. gluteal nerves, sciatic vessels, gr. and lesser sciatic nerves, internal pudic vessels and nerves, and nerves to Obturator internus and quadratus femoris.

Lesser Sacro-sciatic notch transmits tendon of Obturator internus nerve to that muscle, and internal pudic vessels and nerve.

Tuberosity – 3 surfaces.

External –

{ Quadratus femoris
Obturator externus
Adductor magnus

Internal –

{ Transversus perinaei
Erector penis

Posterior surface –

Lower rough triangular part
Upper smooth quadril.

{ Adductor magnus
Great Sacro-Sciatic lig.
Semi membranosus
Biceps and
Semi tendinosus

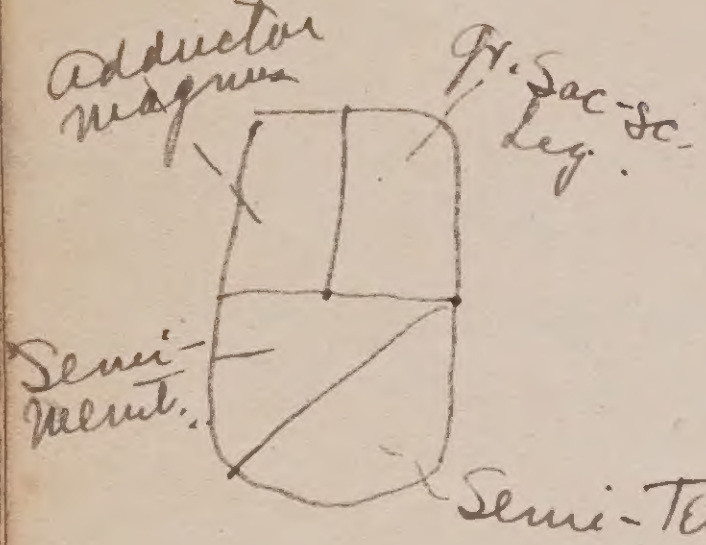

Ramus –

Outer Surface –

Obturator externus
Adductor magnus

Axis of Inlet of pelvis inclines forward at about 67° = toward navel.
Axis of Outlet of pelvis. - 60%
Pelvic canal, 1½ in. in front. 4½-6 behind.
Differences between ♂ and ♀ pelvis
Male Pelvis - Pubic arch V-shaped.
Obturator foramen irregularly oval.
Pelvis deeper and narrower

Female Pelvis - spines of ilium farther apart - pubic arch wider.
Tuberosities farther; spines of ischium point downward ad outward; promontory of sacrum less prominent; sacrum more curved.
Obturator foramen triangular. Pelvis shallower.
Female bones, in general, smaller and lighter; muscular attachments less marked.

Acetabulum - surrounded by a rim of cartilage; rim incomplete (in life) bridged over by transverse ligament).
Fossa acetabuli - for blood vessels and nerves which supply joint and head of femur.
Looks outward and downwards and a little forwards.
Femur articulates with it at an angle

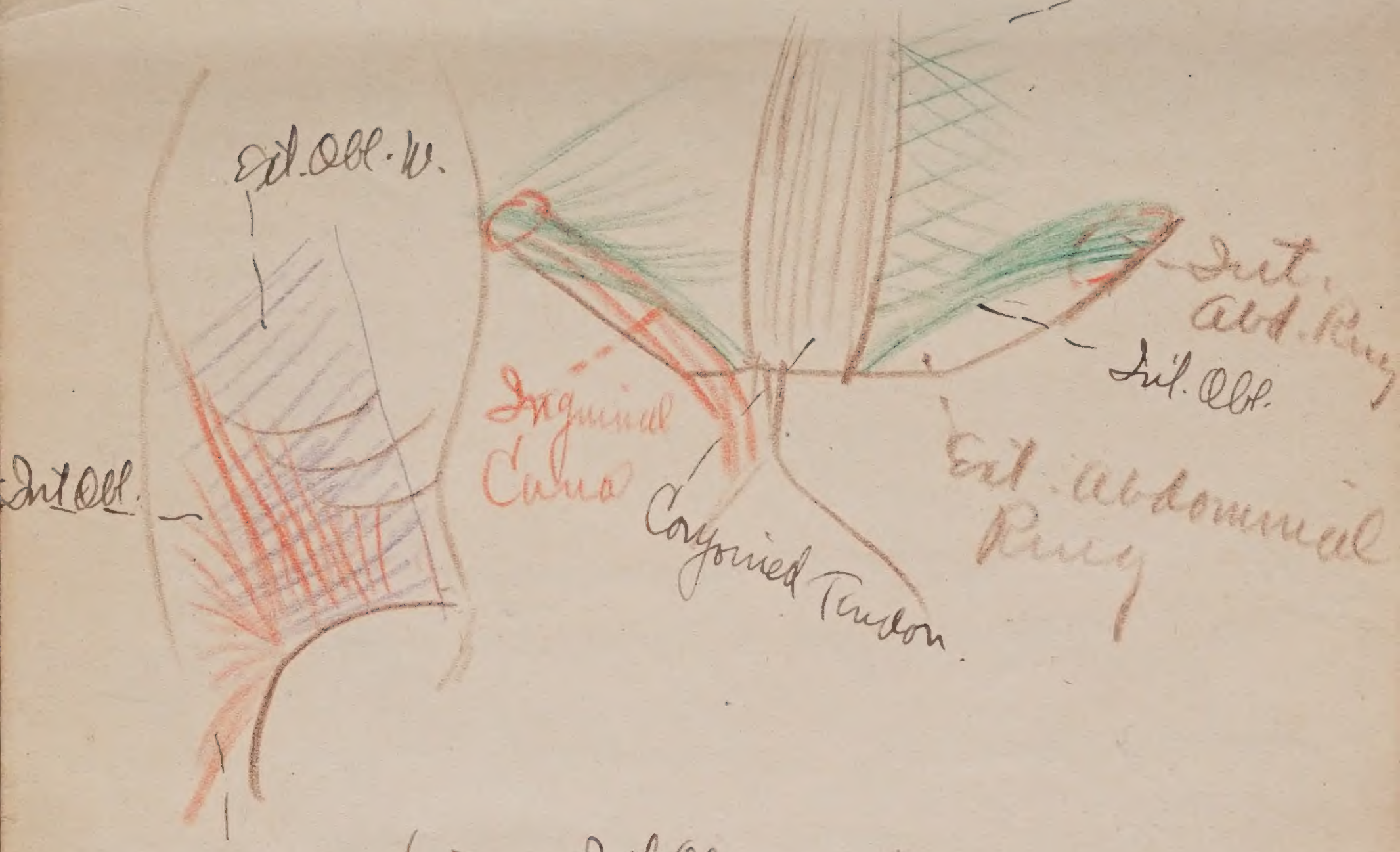

Muscles of Thigh

Deep fascia } surrounds muscles of thigh
Vaginal fascia } like trouser leg.
Fascia lata } Holds muscle in place

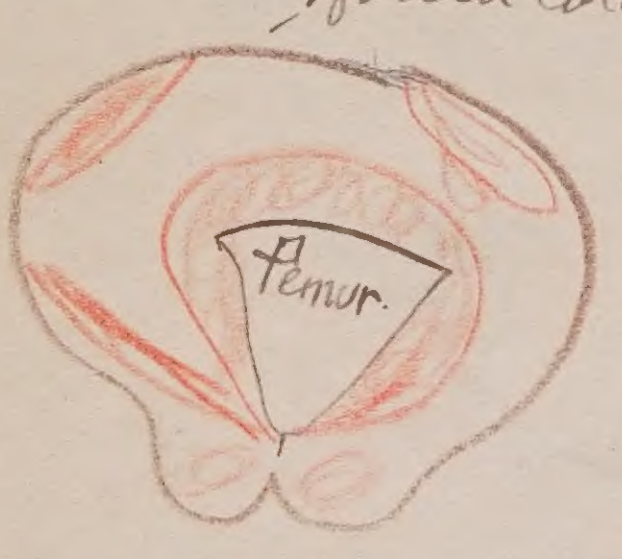

Attached all along crest of Ilium, posteriorly to Sacrum to Great Sacro-Sciatic ligament, rami of Ischium, to Poupart's ligament.

Two layers of fascia in front - covering muscles coming out of pelvis (Iliacus, Psoas, Pectineus), and layer coming around from inner side: the two layers forming a fold in front.

Iliac portion of fascia lata } arising from Poupart's ligament

Ilio-psoas Muscle

Falciform ligament

pubic portion (green) of fascia lata

Long saphenous vein (outlets saphenous opening

Falciform ligament = free edge at junction of Iliac and pubic portions of fascia lata

Saphenous opening. About 1½ inch below spine of pubis.

Deep layer of fascia covers opening = Cribriform fascia perforated for vessels.

Important in operations for femoral hernia.

Fascia lata – pierced by all cutaneous nerves.

Nerves { Middle Cutaneous, Internal ", External " } do not appear at Surface of upper thigh

Muscles – Anterior Aspect.

Quadriceps Extensor } From ant. Sup. Spine of Ilium to tibia

the only muscle on front of thigh

4 portions – Rectus femoris (ant. inf. spine to patella)

Vastus internus } arise from shaft
Vastus externus } of femur

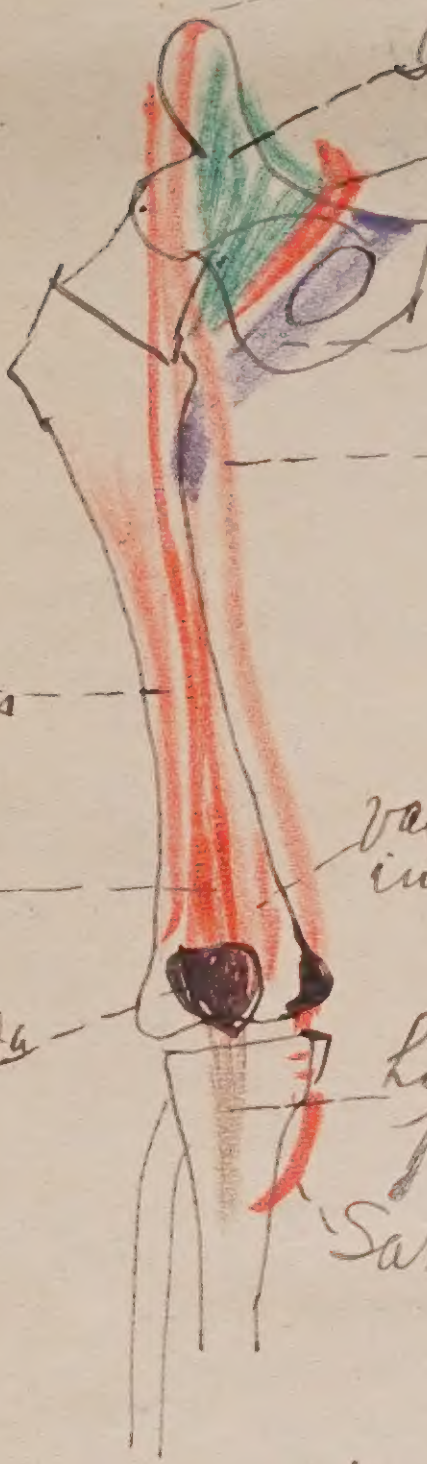

Sartorius — from aut. sup. spine passes around inner condyle & inserted in tibia

4 portions of Quadriceps Extensor are inserted into patella.

Ligamentum patellae = tendon of Quadriceps Extensor carried down to insertion into tibia. Lig. patellae is homologous to Olecranon process of Ulna.

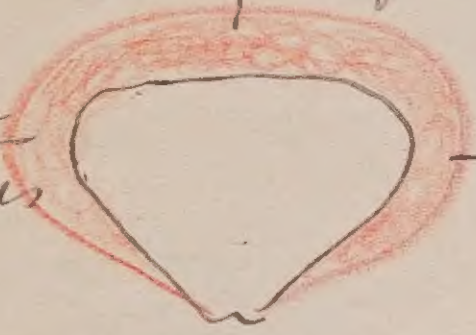

Cross-Section of Femur





Patella is with difficulty displaced Externally — ∴ fibres of vastus externus placed high upon patella — and fibres of vastus internus extend down on inner side of patella

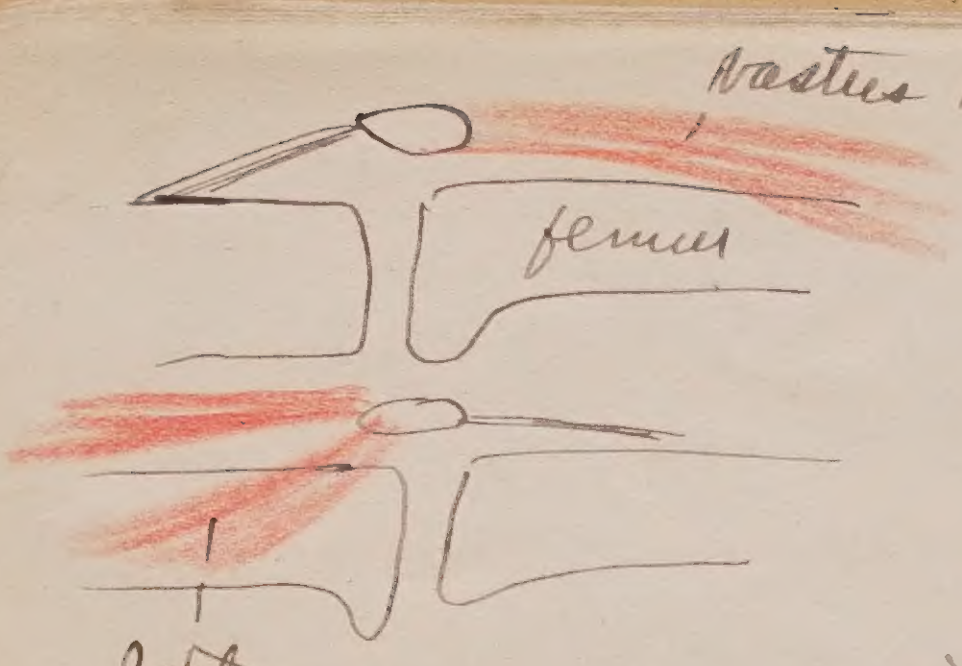

External Side view

Internal Side view.

∴ Outer side of femur is uncovered for some distance.

Patella is a sesamoid bone in Quadricep Extensor, like Pisiform in tendon of Flexor carpi ulnaris.

Psoas and Iliacus: Iliacus arises in iliac fossa, passes out beneath Pouparts ligament to lesser trochanter of femur.

Psoas – arises from lateral aspect of bodies of 5 lumbar vertebrae and their transverse processes, skirts brim of pelvis, inserted with iliacus into lesser trochanter

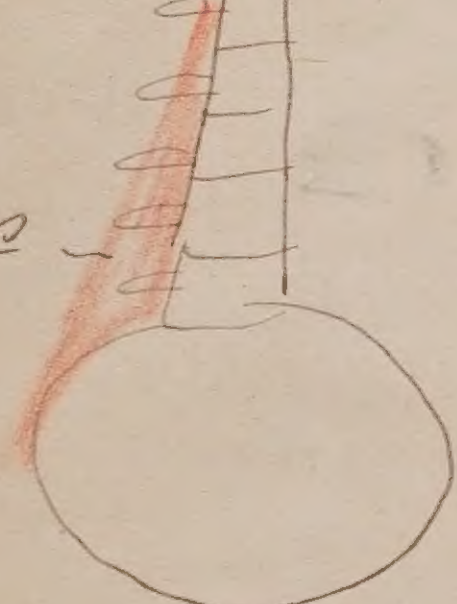

Pectineus – arises from os pubis – pectineal line, passes outward to be inserted into inner lip of linea aspera.

Muscles of Innominate Bone 4 groups.

1. To Trunk
2. Perineum & Generative Organs
3. Femur
4. To Tibia & Fibula.

To Trunk - Latissimus dorsi, Quadratus lumborum, Erector spinae

To Leg - Rectus femoris, Sartorius, gracilis

Hamstring Muscles { Biceps, Semi tendinosus, Semi membranosus

From ant. Bord. Ilium & tuberosity of Ischium and gracilis from Os pubis

~~To Femur~~ External Rotators - & gemelli
adductor brevis - upper 1/3 - linea aspera
Adductor magnus - middle 1/3 "
Adductor longus - all of " "
(all from outer and inner surface of Ilium)

Motions

Thigh - Flexion
Extension
Abduction (spreading apart)
Adduction (drawing together)
External Rotation
Internal Rotation
Circumduction

Leg - Flexion
Extension
Very little lateral movement or rotation

~~Foot~~ - Flexion of foot Bending foot up
(Extensor of toes flex foot.
Extension of foot - same muscle flex the toes
Eversion } - sole outward } like pronation
Inversion } " inward } & supination of hand

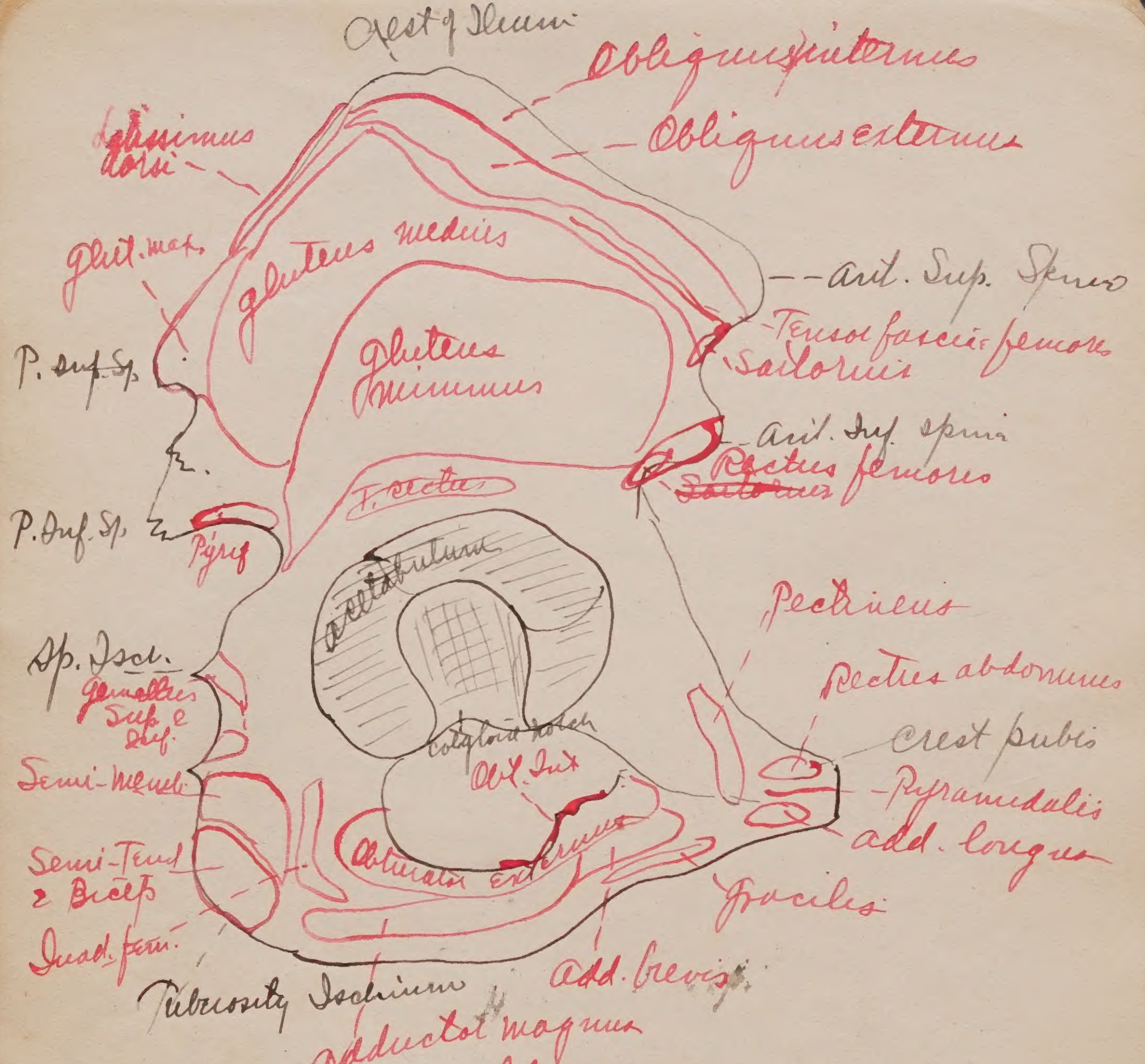
Crest of Ilium
Obliquus internus
Obliquus externus
Latissimus dorsi
Glut. max.
Gluteus medius
ant. Sup. Spine
Tensor fasciæ femoris
Sartorius
P. Sup. Sp.
Gluteus minimus
ant. Inf. spine
Rectus femoris
Sartorius
R. rectus
P. Inf. Sp.
Pyrif
acetabulum
Pectineus
Sp. Isch.
Gemellus Sup & Inf.
Rectus abdominis
cotyloid notch
Crest pubis
Obt. Int
Semi-Memb.
Pyramidalis
add. longus
Obturator externus
Semi-Tend & Bicep
Gracilis
Quad. fem.
add. brevis
Tuberosity Ischium
adductor magnus

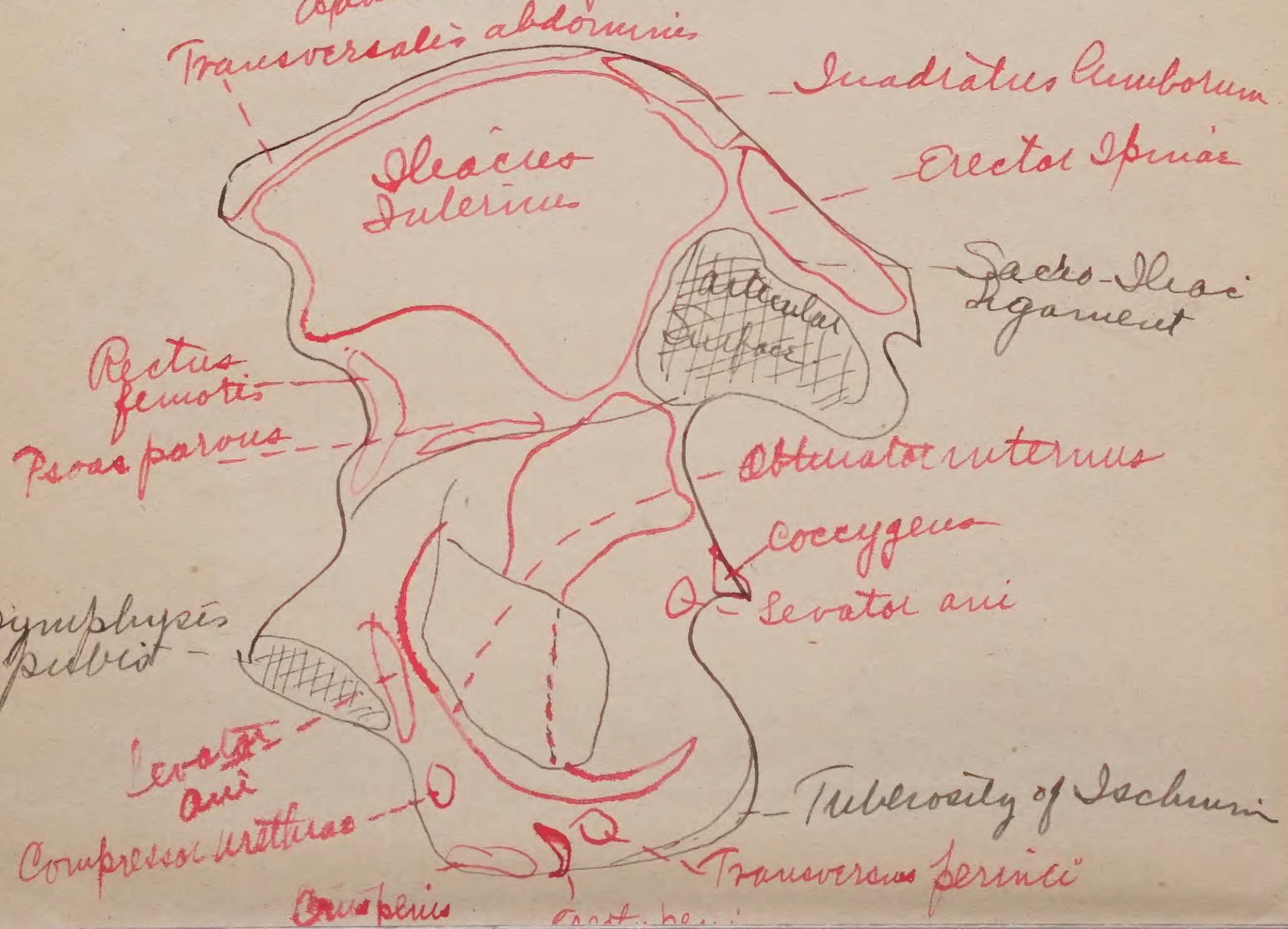
Transversalis abdominis
Quadratus lumborum
Iliacus Internus
Erector Spinae
Sacro-Iliac Ligament
articular surface
Rectus femoris
Psoas parvus
Obturator internus
coccygeus
Levator ani
Symphysis pubis
Levator ani
Tuberosity of Ischium
Compressor urethrae
Transversus perinei
Crus penis
Crest. p

Femur –

Head – directed upward, inward, forward.

Neck –

Anterior surface – vascular foramina

Posterior surface – capsular ligament.

Superior border – short, thick.

Inferior border – long, narrow.

Great Trochanter.

External surface – quadrilateral.

{ Gluteus medius

Internal surface – Digital or trochanteric fossa, for

{ Obturator externus; –
Obturator internus
Gemelli

~~Superior border~~

{ Pyriformis –

Inferior border –

{ Vastus Externus

Anterior Border –

{ gluteus minimus

Posterior Border.

Lesser Trochanter –

Internal border ^continuous with^ lower border of neck;

External " – Post. Intertroch. line

Inferior – mid. div. linea aspera

{ Ilio-psoas

Tubercle of Femur – upper and front part of neck at junc. with great trochanter.

{ Gluteus minimus
Vastus externus
Obturator internus
Gemelli } 5 muscles meet.

Spiral line or
Ant. Intertrochanteric line } runs obl. down & inward from tubercle.
terminates in linea aspera.
Ilio-femoral ligament.
{Vastus internus.

Posterior Intertrochanteric line – down from summit of Gr. Troch. posteriorly.
= linea quadrati.
{Quadratus femoris
{Adductor magnus (few fibres)

Shaft –
Linea aspera = ✗
External ridge = Gluteal ridge
{Gluteus maximus
{Vastus externus
Middle Ridge – to base of L. Troch.
Internal Ridge – to spiral line
{Vastus internus
Below, terminates in 2 ridges,
space between = Popliteal surface

Inner ridge.
Adductor tubercle
{ Adductor magnus

{Short head of Biceps – below
{betw. ~~Glut. max.~~ Vastus Ext. and
{add. magnus.

Between add. mag. & Vast. int.
{ Iliacus } above
{ Pectineus }

{ adductor brevis } below
{ adductor longus }

Anterior ~~Surface~~ —
{ Crureus
Sub-crureus.

Lower Extremity —
2 Condyles —
Intercondyloid Notch — behind
Trochlea — in front.

~~Internal Condyle — long, narrow.~~
External Condyle — broad
{ Gastrocnemius — outer head
{ ~~Plantaris~~
Outer tuberosity
{ Popliteus muscle

Internal Condyle —
Outer tuberosity
{ Internal lat. ligament
{ Gastrocnemius — inner head.

23 Muscles Attached
To Great Troch. — Gluteus medius, G. minimus, Pyriformis, Obt. int., Obt. ext., Gemellus Sup. and inf.; Quadratus femoris.
Lesser Troch. — Psoas magnus, Iliacus.
Shaft — Vastus ext.; Glut. max.; Biceps (short h.) Vastus int.; Add. magnus, Pectineus, Add. brevis, Add. longus, Crureus, Sub-crureus
Condyles — Gastrocnemius, Plantaris, Popliteus

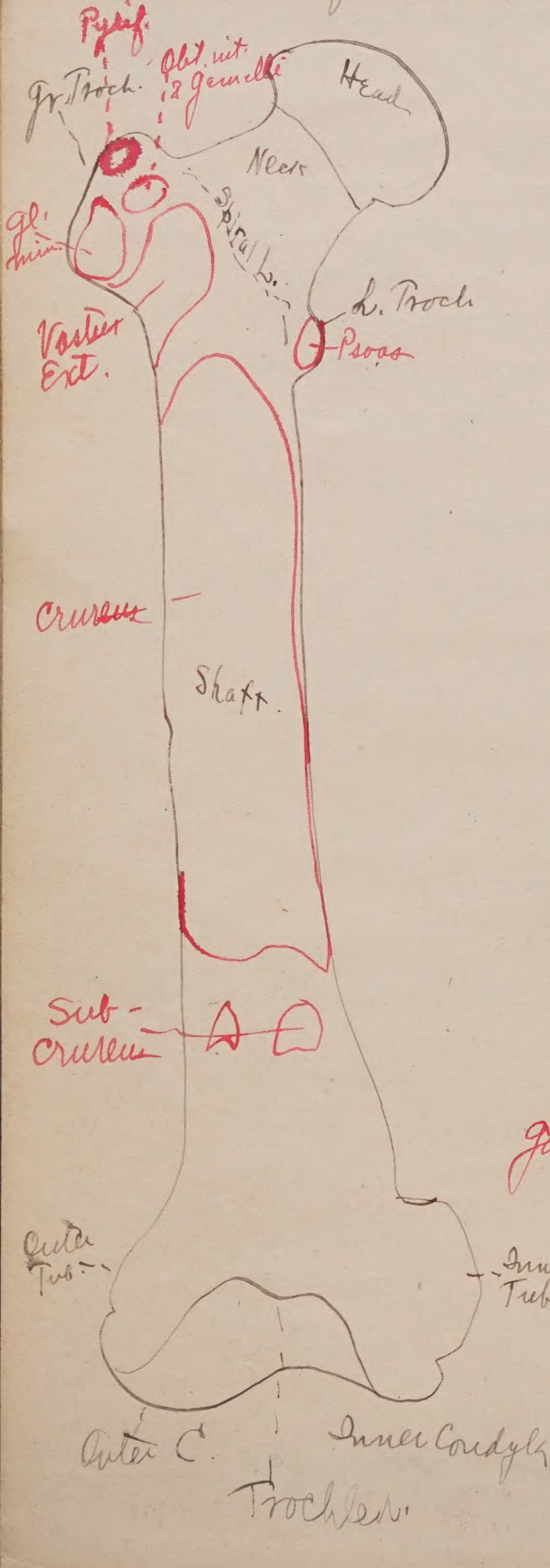
Anterior Surface
Pyrif.
Obt. int. & Gemelli
Gr. Troch.
Head
Neck
Spiral L.
Gl. min.
L. Troch
Psoas
Vastus Ext.
Crureus
Shaft.
Sub-Crureus
Outer Tub.
Inner Tubercle
Outer C.
Inner Condyle
Trochlea.


Posterior Surface
Digital Fossa
Head.
Glut. med.
Quad. fem
Psoas
Iliacus
Pectineus
Gluteus maximus
Adductor brevis
Vastus Ext.
Adductor longus
Adductor magnus
Vastus Internus
Biceps (short head)
Gastrocnemius
Popl. Space
Plantaris
Popliteus
Inner Con.
Outer Condyle
Intercondyloid notch

Tibia —

Head - Upper Extremity -

2 Tuberosities - artic. with condyles - femur.

Spinous process of tibia -

Tubercle - ant. surf., attach. Lig. patella.

Popliteal Notch - posterior.

Posterior crucial ligament.

Posterior ligament

Inner tuberosity -

{ Semi-membranosus.

Outer tuberosity - artic. with fibula.

{ Extensor longus digitorum

{ Biceps

Shaft -

Anterior border - crest of tibia - shin

Deep fascia of the leg.

Internal border -

Internal lateral ligament

{ Popliteus (

{ Soleus

{ Flexor longus digitorum middle $\frac{1}{3}$

External border - Interosseous ridge

Interosseous ligament.

Internal surface -

{ Sartorius tendon, apon. (upper $\frac{1}{3}$

{ Gracilis

{ Semi tendinosus

Lower part subcutaneous

External surface -

{ Tibialis anticus (upper $\frac{2}{3}$).

Lower $\frac{1}{3}$ cov. by tendons of

Tib. antic., Ext. prop. hallucis and

Ext. long. digitorum

Posterior surface —
Oblique line — upper part —
Popliteus muscle & fascia
Soleus
Flexor longus digitorum
Tibiales posticus
Middle part = vertical ridge —
Flexor longus digitorum (inner ½)
Tibiales posticus
Tibiales posticus
Flexor longus digitorum
Flexor longus hallucis.
Lower Extremity — 5 surfaces
Inferior surface — quadrilateral, artic. with astragalus.
Anterior surface — cov. by Extensor tendons
Ant. lig. of ankle joint
Posterior surface —
Groove tendon of Flex. l. hallucis.
Ext. surface —
Inf. Interosseous ligament.
Ant. and Post. Inf. Tibio fibular lig.
Internal surface prolonged to form
Internal malleolus — inner
surface convex & subcutaneous;
12 Muscles attached —
Inner tuberosity — Semimembranosus
Outer " + Tibialis anticus, Ext. l. dig. & Biceps
Shaft — int. surf. — Sartorius, gracilis & Semitendinosus
Ext. surf. Tibialis anticus.
Post. surf — Popliteus, Soleus, Flex. l. digitorum
Tibialis posticus.
Tubercle — Ligamentum patellae — Quadriceps extensor
Tensor fasciae femoris indirectly thro' Ilio-tibial band.



Anterior Surface. Tibia

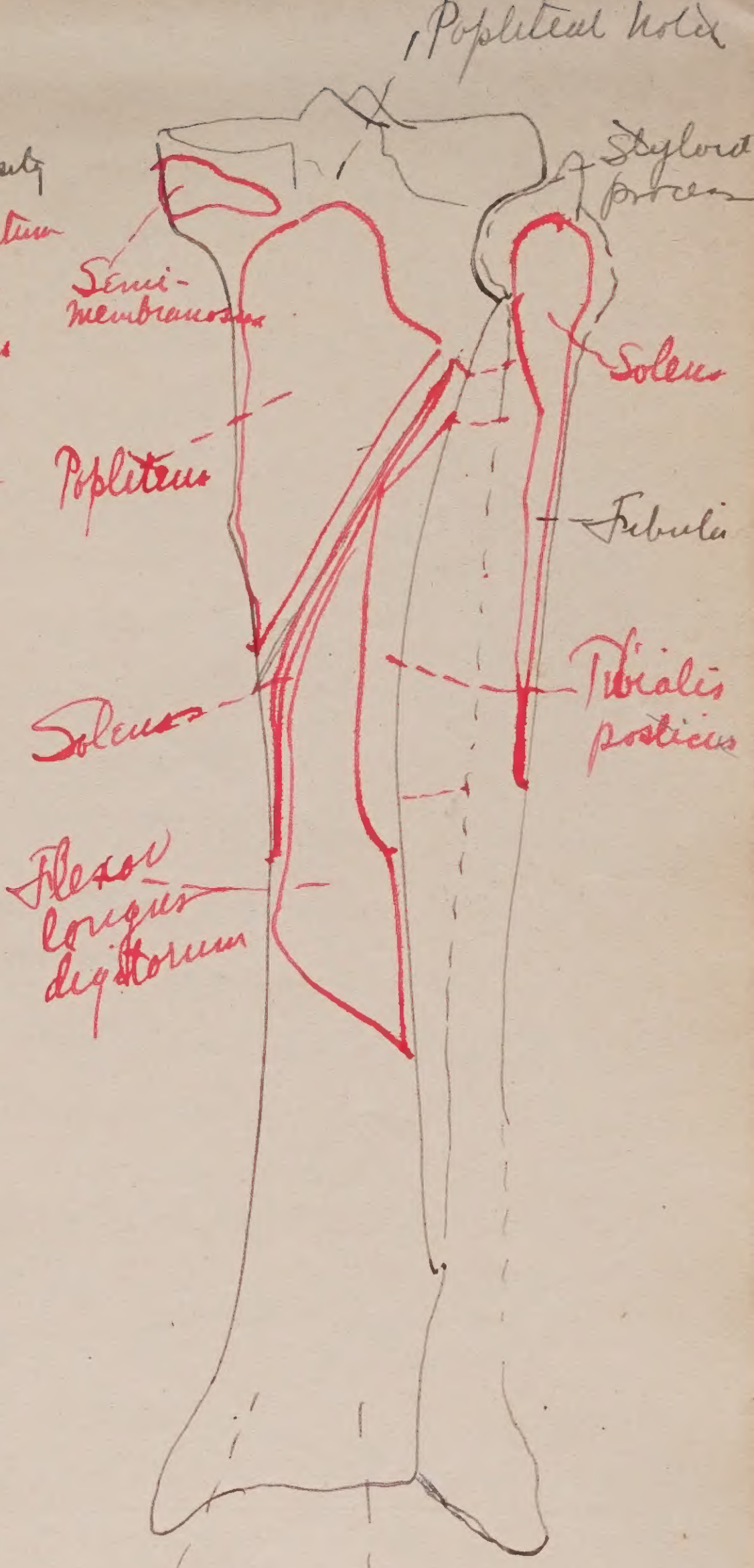

Posterior Surface

Groove for Flexor longus digitorum Tibialis posticus

Groove for Flex. l. hallucis

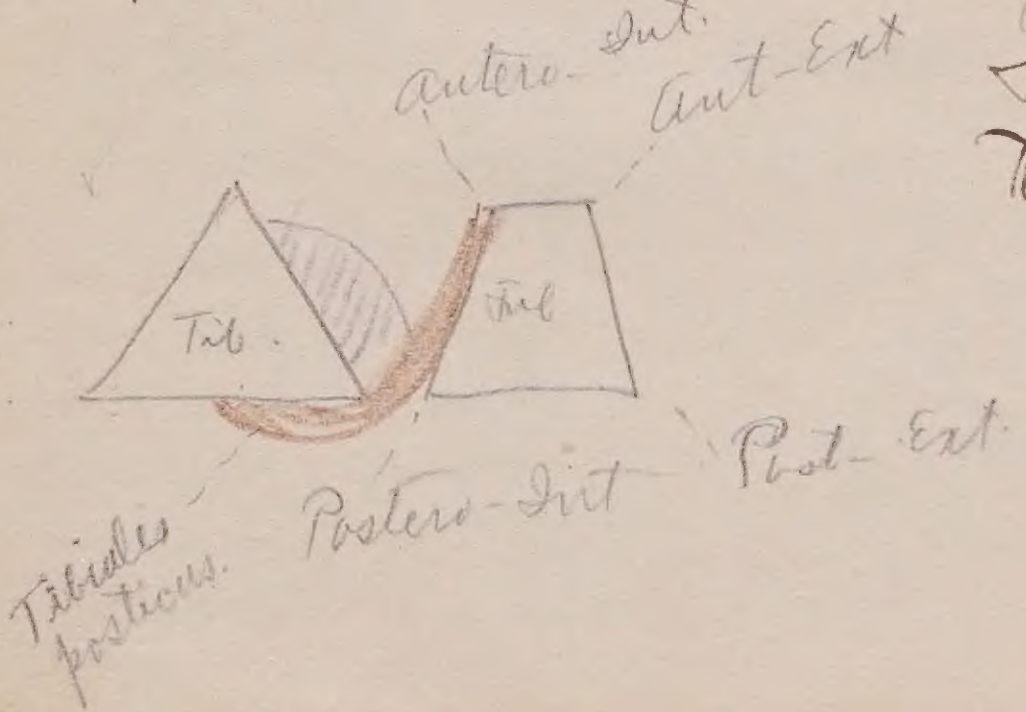

Patella - triangular, with apex downward.

Front-top - Rectus femoris
Lateral - Vasti ext. and int.

Internal - narrower, articular facet.
Outer facet broader.

Fibula

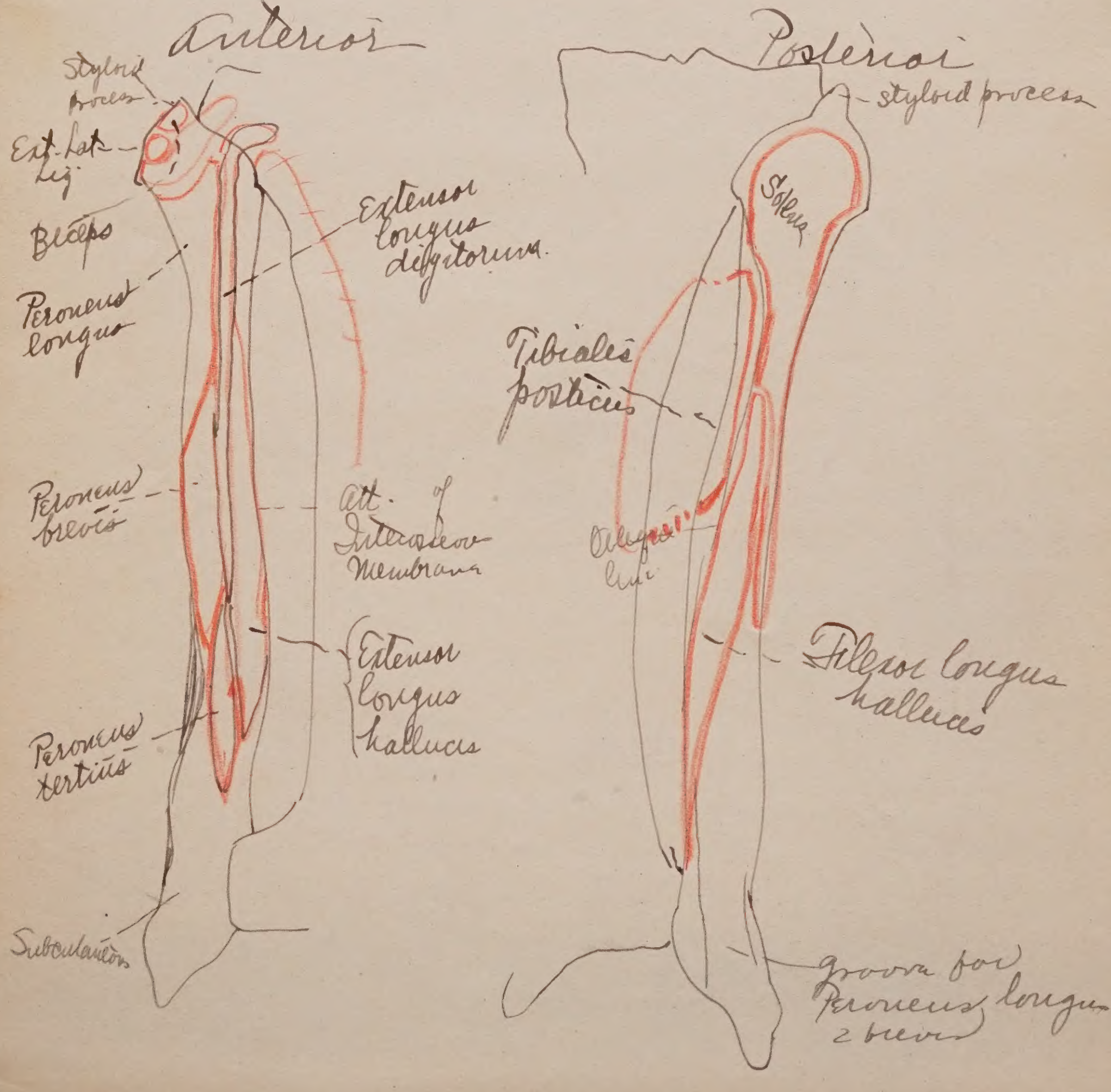

Head - irregularly quadrate.
articular facet - with ext. tuberosity of tibia.
Styloid process.
{ Tendon of Biceps
for Ext Lateral ligament of Knee
Summit - to Short ext. lat. lig.
{ Peroneus longus
| Soleus.

External Malleolus - pyramidal -
Ext. surf - sub-cutaneous
Int. surf - △ facet, art. with astragalus.
Ant. Border - Ext lat. lig.
Post. border - groove for tendons Peroneus { longus / brevis

Shaft - 4 borders - 4 surfaces.
Antero-External border - from front of head - bifurcates above outer surf. Ext. Malleolus.
Antero-internal (Interosseous) - close to inner side of preceding - terminates at apex of rough △ surf. above artic. facet of Ext. Mall.
Postero-external - base of styloid process to post. border of outer malleolus.
Postero-internal - (Oblique line) - from inner side of head, terminates by becoming continuous with Ant-Int. border at lower ¼ of bone.
Well marked at upper and middle parts of the bone.

Nine muscles attached to Fibula
To Head - Biceps, Soleus, Peroneus longus.
Shaft -
ant-surface - Ext. longus digitorum, Peroneus tertius, Ext. proprius hallucis.
Ant - 3. Int. surface - Tibialis posticus
Ext - 2. Post. surface - Soleus, Flexor longus hallucis
Post - 2. Ext. surface - Peroneus longus, Peroneus brevis.
Int - 1.

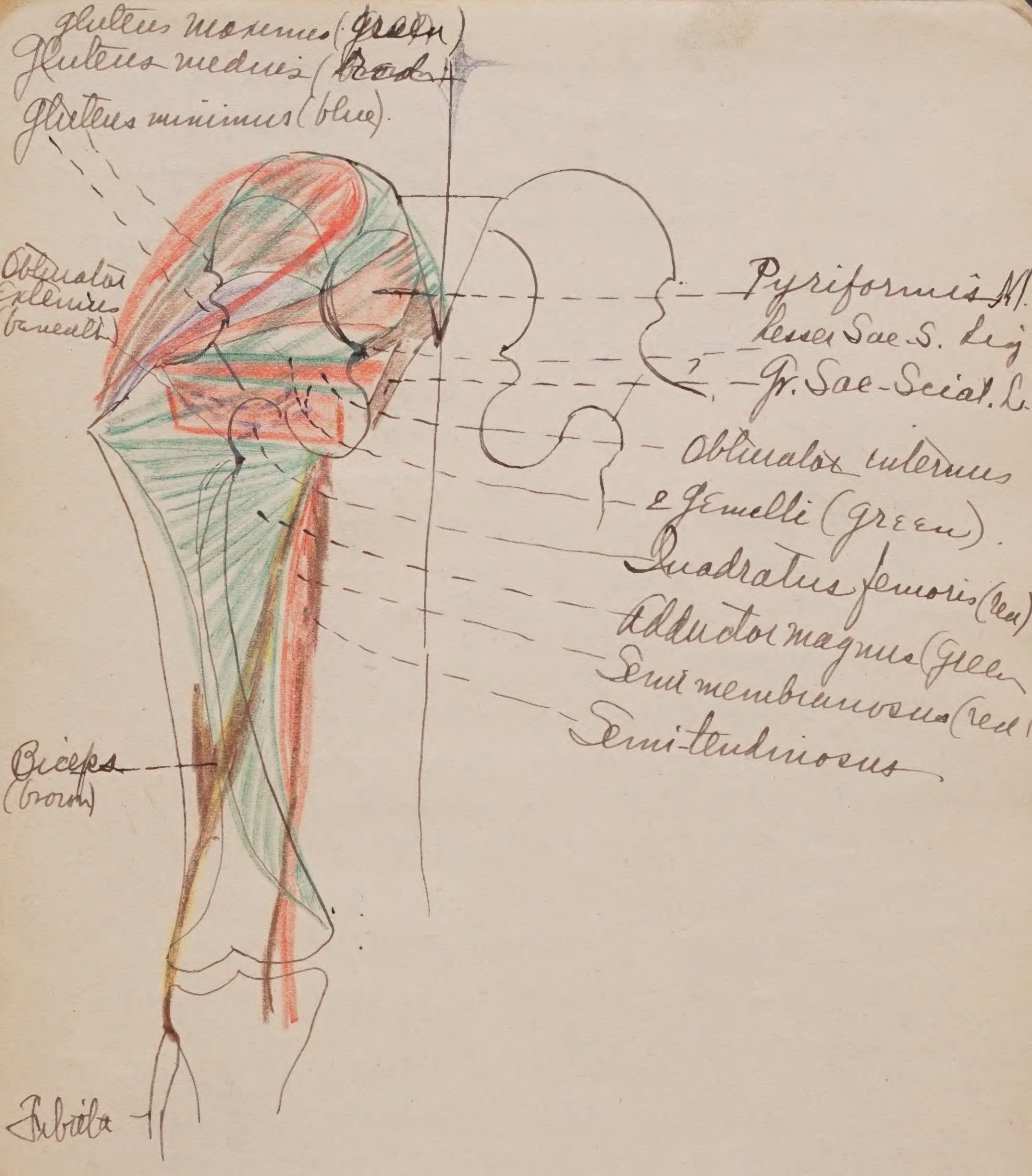

Great ~~Sacro~~-sciatic nerve passes out of G. Sacro-sciatic notch below pyriformis muscle, and passes down outside of thigh muscle.

All Sup. gluteal Nerves pass out above Pyriformis muscle, all other passing thru Sacro-sci. notch pass below it

Pyriformis Muscle comes out from great sacro-sciatic notch - to

Obturator internus -
Inserted on greater trochanter.
Reinforced by two Gemelli (Sup. & Inferior)
Gemellus Superior
Gemellus Inferior
Quadratus femoris

Adductor magnus -
Desc. ramus of pubis, ramus of isch. & tuberos. of isch. inserted along whole of linea aspera.

Hamstring Muscle
Biceps (2 heads) Tuberosity of isch. & lower ½ Shaft Fem. Inserted into head of fibula
Semi-Tendinosus - Tuberosity of Ischium - to inner aspect tibia just below tuberosity
Semi-Membranosus -
Tuberos. of isch. to inner

Glutei Muscles -
Gluteus minimus - from below Inf. curv. line to
" medius -
Gluteus maximus - when dissected off, uncovers most of posterior femoral muscles - Inserted into gluteal ridge

Adductor Muscles –

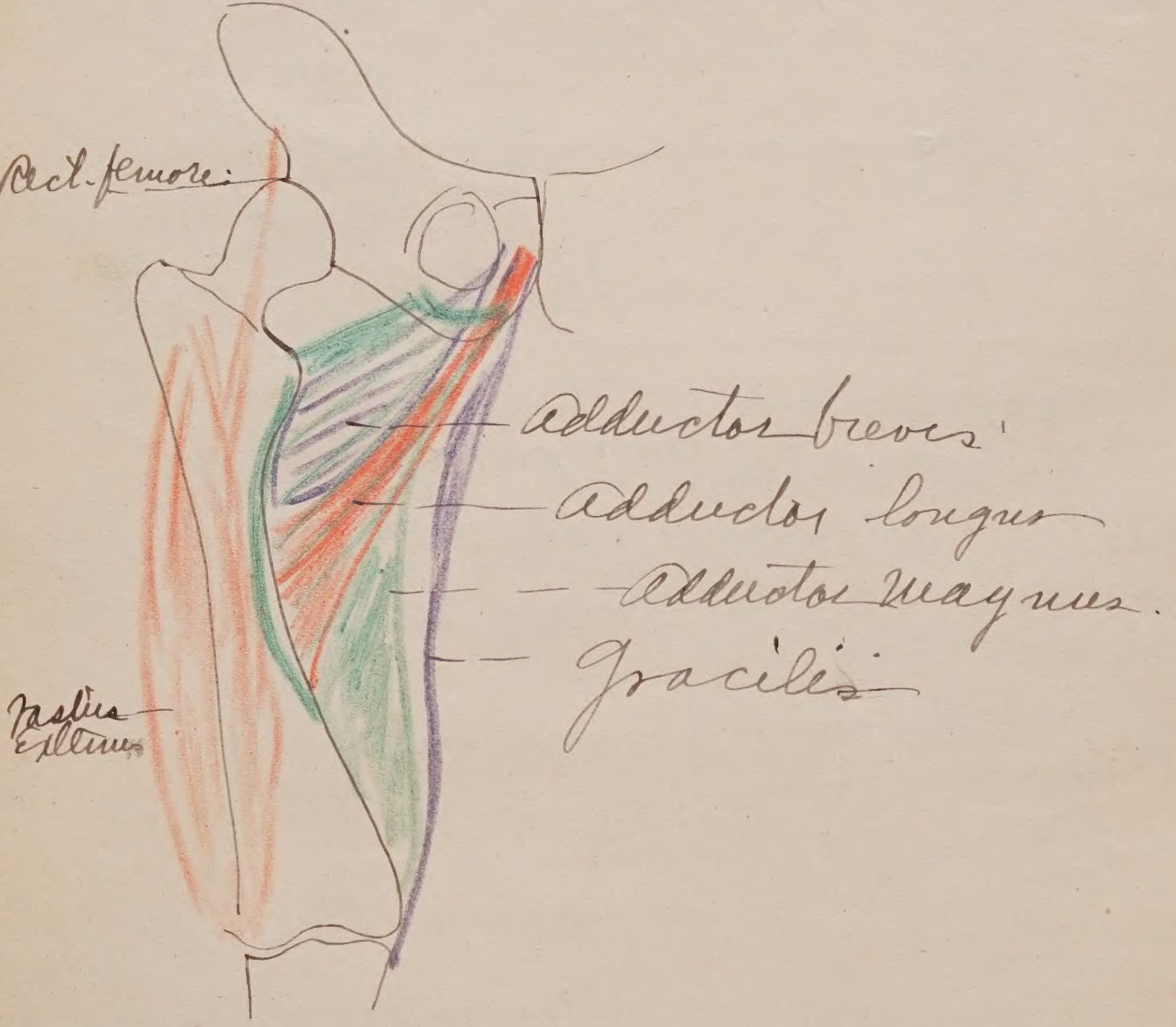

Adductor magnus –

Inserted into posterior border of femur – whole length

Adductor longus on top of Adductor magnus – inserted middle $\frac{1}{3}$ of posterior border of femur

Adductor brevis – Upper $\frac{1}{3}$

Pectineus – inserted into middle lip – covers adductor brevis

Gracilis arises from body of Os pubis
— inserted into inner aspect of tibia just below the tuberosity.

3 Surgical Spaces in thigh:

Scarpa's Triangle — upper 1/3 of thigh, anterior.

Hunter's Canal — middle & inner 1/3 of thigh

Popliteal Space — lower and posterior 1/3 of thigh.

Position of these spaces due to winding of femoral artery around thigh

Scarpa's △ — upper and anterior third of thigh.

Boundaries
Upper — Poupart's lig
Inner — Adductor longus
Outer — Sartorius
~~Base~~ —

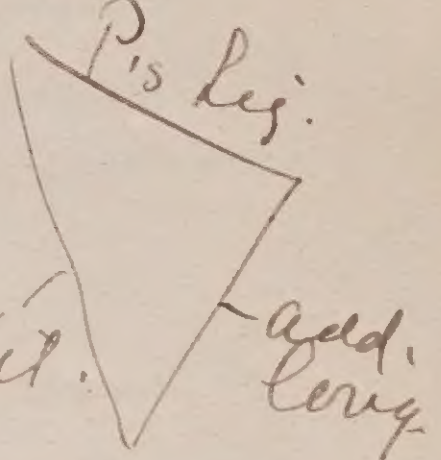

Hunter's Canal —



Roof — fascia from vasti to Adductor muscle
Inner — Adductors longus and magnus
Outer — Vastus Internus.

3221

Foot – forms an arch. 

Weight of body rests upon tibia and astragalus.



Os calcis
Cuboid

1st Arch { Os calcis, Cuboid } on outer side

2nd Arch { Astragalus, Navicular, 3 Cuneiform }

2 arches in Foot –

1 arch – with both Extr. on ground –

1 arch. post. extremity rests on ground, the anterior on other arch.

Os Calcis (heel-bone) – largest

Astragalus

Cuboid – in front of os calcis

(navicular) Scaphoid

Cuneiform { External, Middle, Internal } –

Longitudinal Arch (2 parts)

Transverse Arch — made up of 4 anterior bones.

Each cuneiform artic. with one metacarpal and Cuboid with the other two metacarpals.

Arch held in place by 2 means:

Long plantar ligament from Os calcis to Cuboid and thence to metatarsals.

Insertion of Tibialis posticus

Various smaller muscles.

Ligaments occasionally give away.

Stretching of ligaments cause stretching of tendons of Muscles.

Flat-feet. Splay footed. Condition due to relaxation of ligaments, causing arch to drop down.

Arch of foot higher on inner than on outer side.

Subcutaneous markings:—

Tuberosity of Navicular — prominent on inner side.

Tuberosity of 5th Metatarsal

Tuberosity of Cuneiform Bone

Os Calcis —

Lesser process — projection on inner side below astragalus

Greater process — in front.

6 Surfaces.

Peroneal ridge on outer surface.

Achilles tendon on upper part

Astragalus - shaped like a die
6 surfaces
Superior surf - art. fac. for tibia.

Potts' fracture - by turning out foot, - breaks off malleoli:
Astragalus points inward, & Os Calcis outward.

Navicular - tuberosity on inner side is subcutaneous. Art. surf. has 3 facets for cuneiform bones
Cuboid - ridge on lower surface with groove in front of it

3 Cuneiform bones - all wedge shaped
Inner largest, base downward

Middle smallest of 3
External - smaller than internal

Muscles of Leg:

Anterior — Flexors of Foot — Tibialis anticus Ext. long. digitorum, Ext. long. hallucis, Peroneus tertius. Tibialis anticus — inverter of foot.

Peroneal — everters of foot. — Peroneus tertius Peroneus longus, Peroneus brevis

Superficial Posterior — Extensors of foot. Gastrocnemius, Plantaris, Soleus.

Deep Posterior Tibialis posticus, Flexor long. digitorum, Flexor longus hallucis

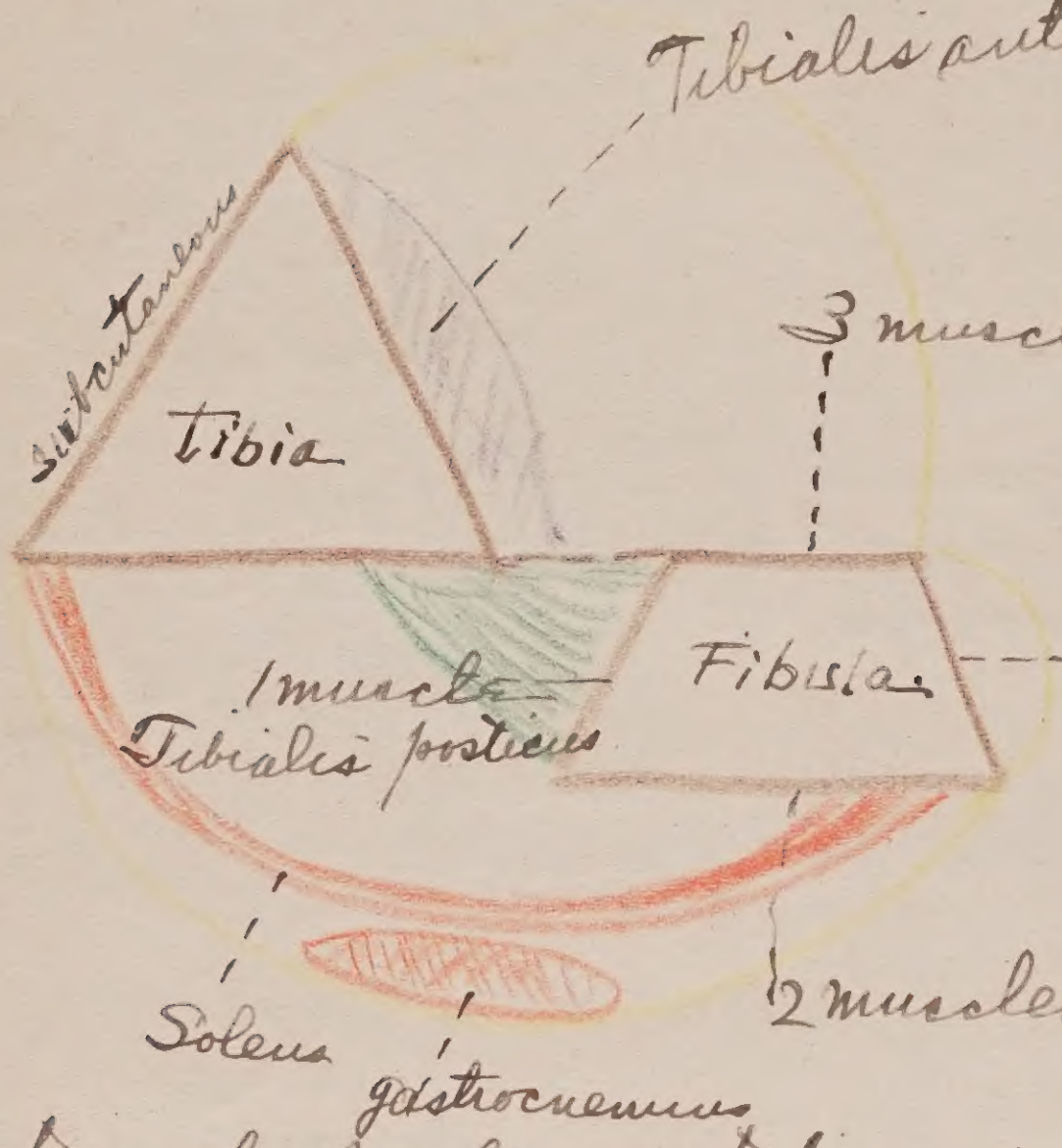

Internal surface of tibia subcutaneous

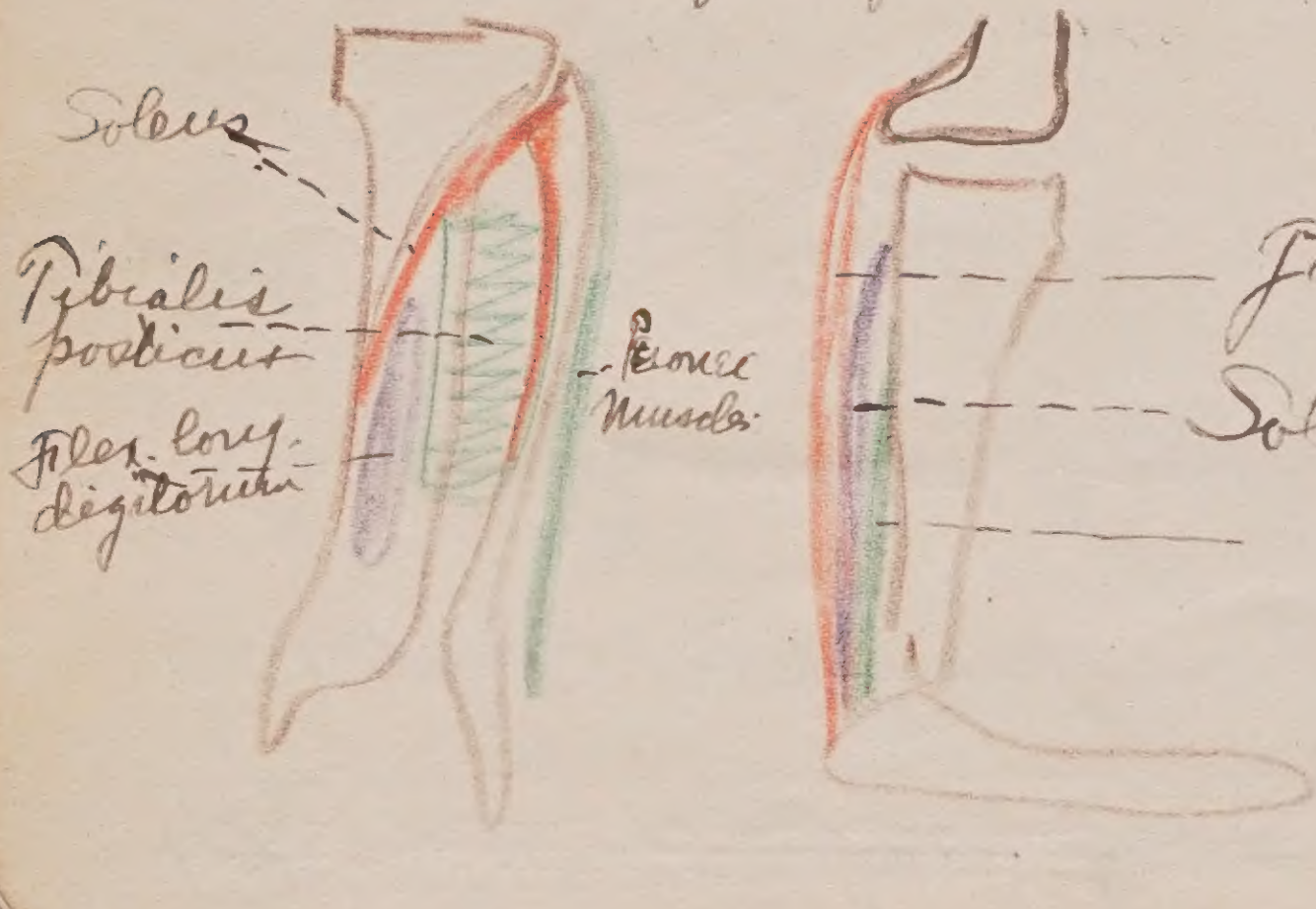

3 planes of Muscle

Gastrocnemius — Superficial layer

Soleus (middle)

~~2 — Bobcat — Muscles~~

Arches of Foot –

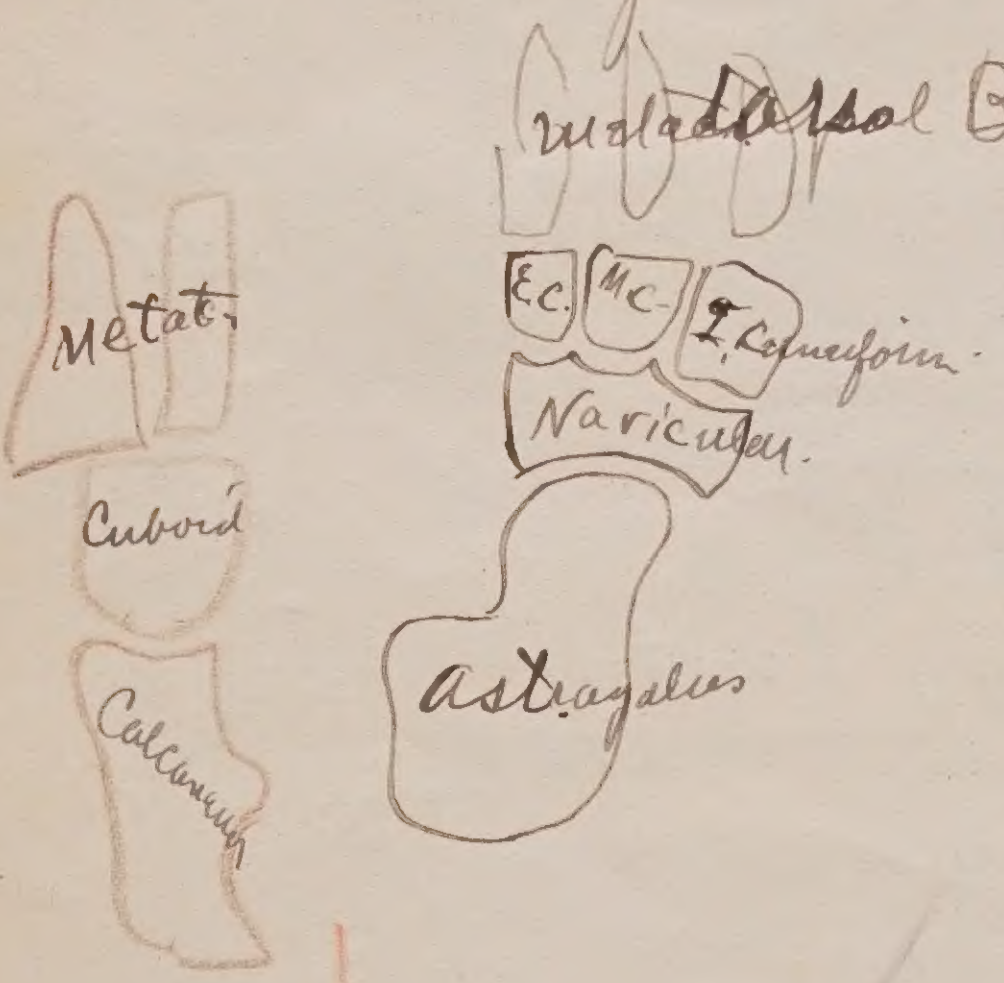

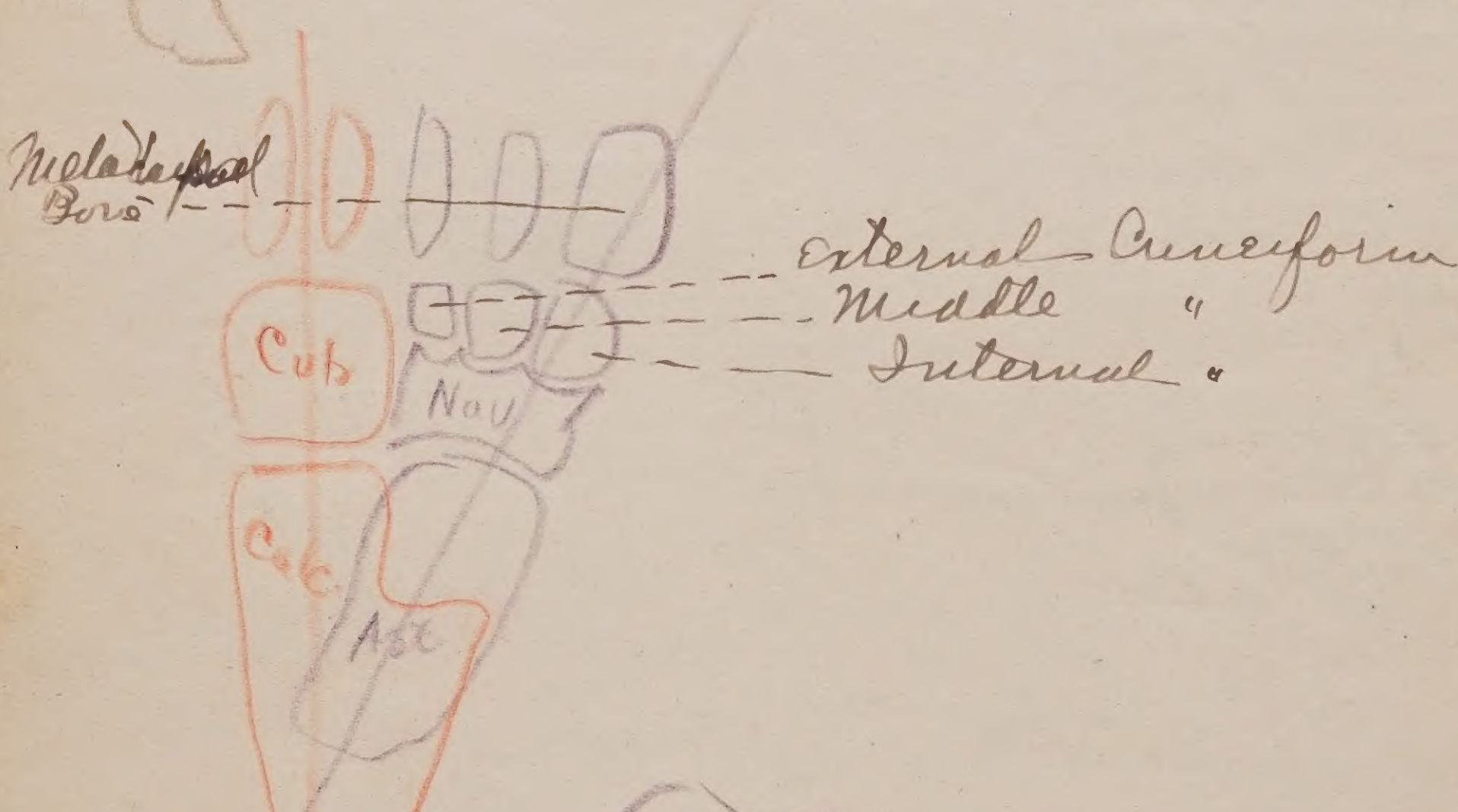



Great or Internal Arch of foot

Lesser or External Arch of Foot.

Transverse Arch -

2 Tibial Muscles

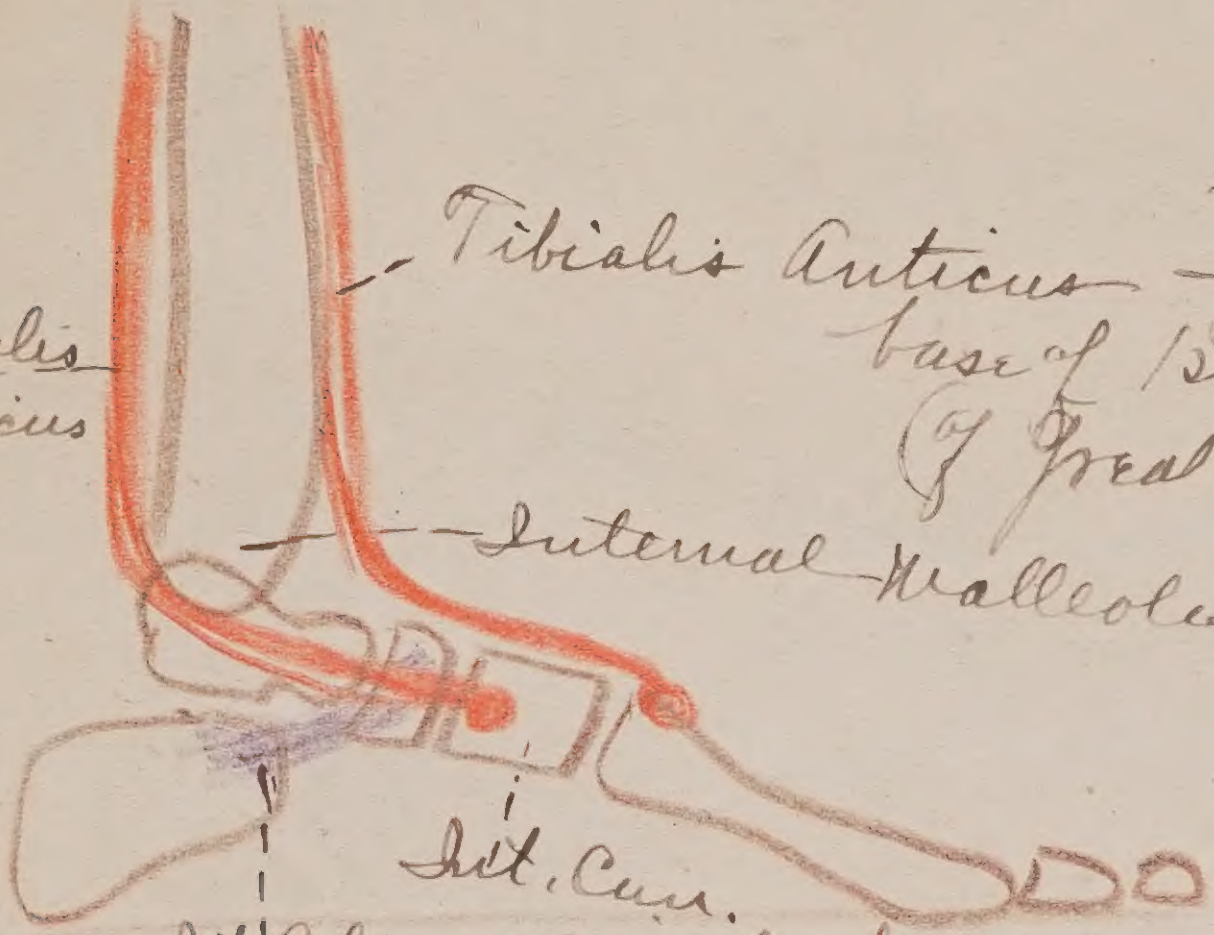

Inserted into Internal Cuneiform (also sends slips to other muscles.

Peronei Muscles.

Peroneus longus (Big toe)
Peroneus brevis (Little toe underneath)
} Inserted into base of Metatarsal bone

Peroneus tertius On top

Internal Calcaneo-Navicular Ligament holds arch of foot together - Reinforced by the great Tibialis posticus tendon. An elastic ligament, containing many yellow elastic fibres. When this ligament gives way, flat-foot is caused

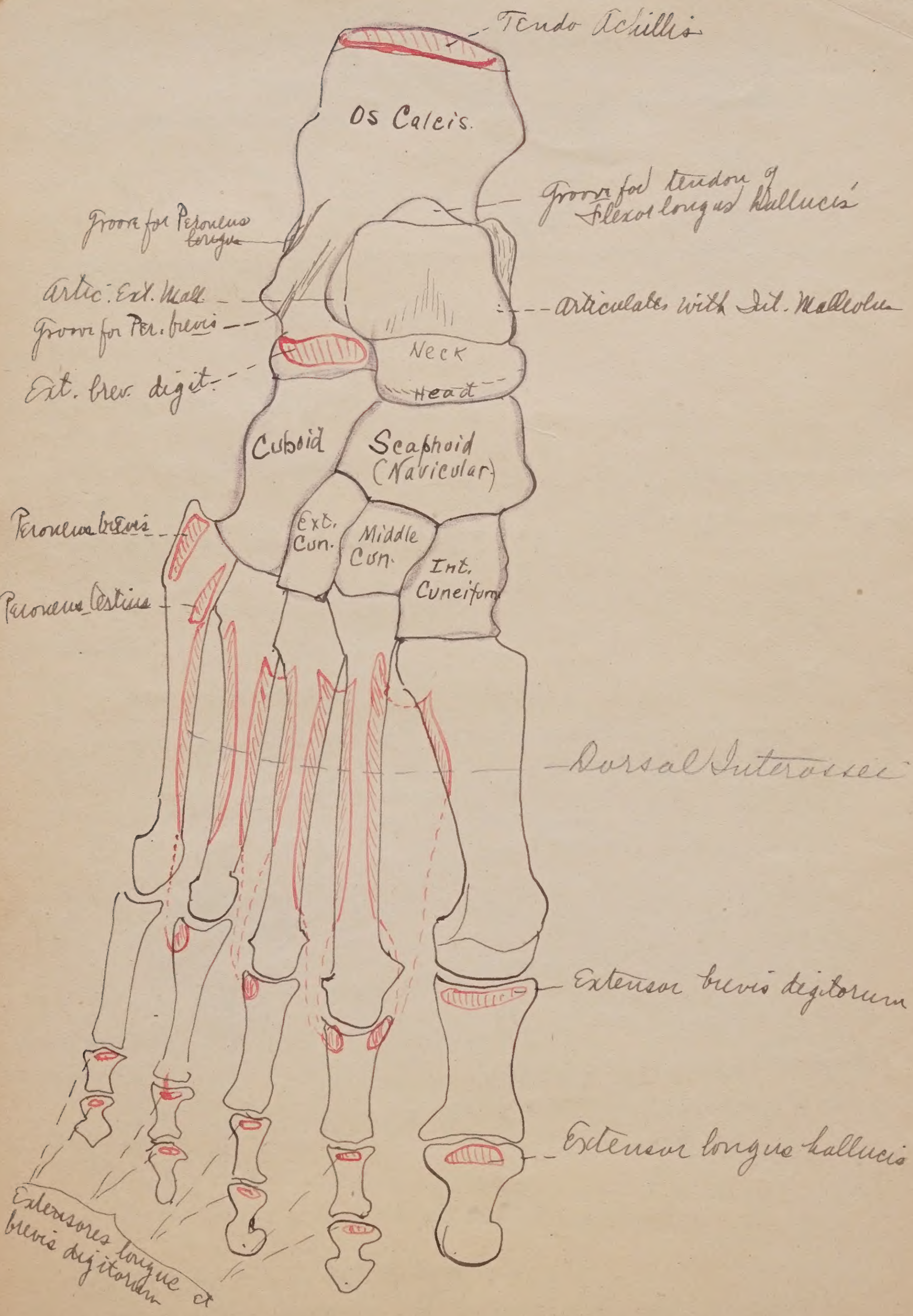

Right Foot – Dorsal surface –

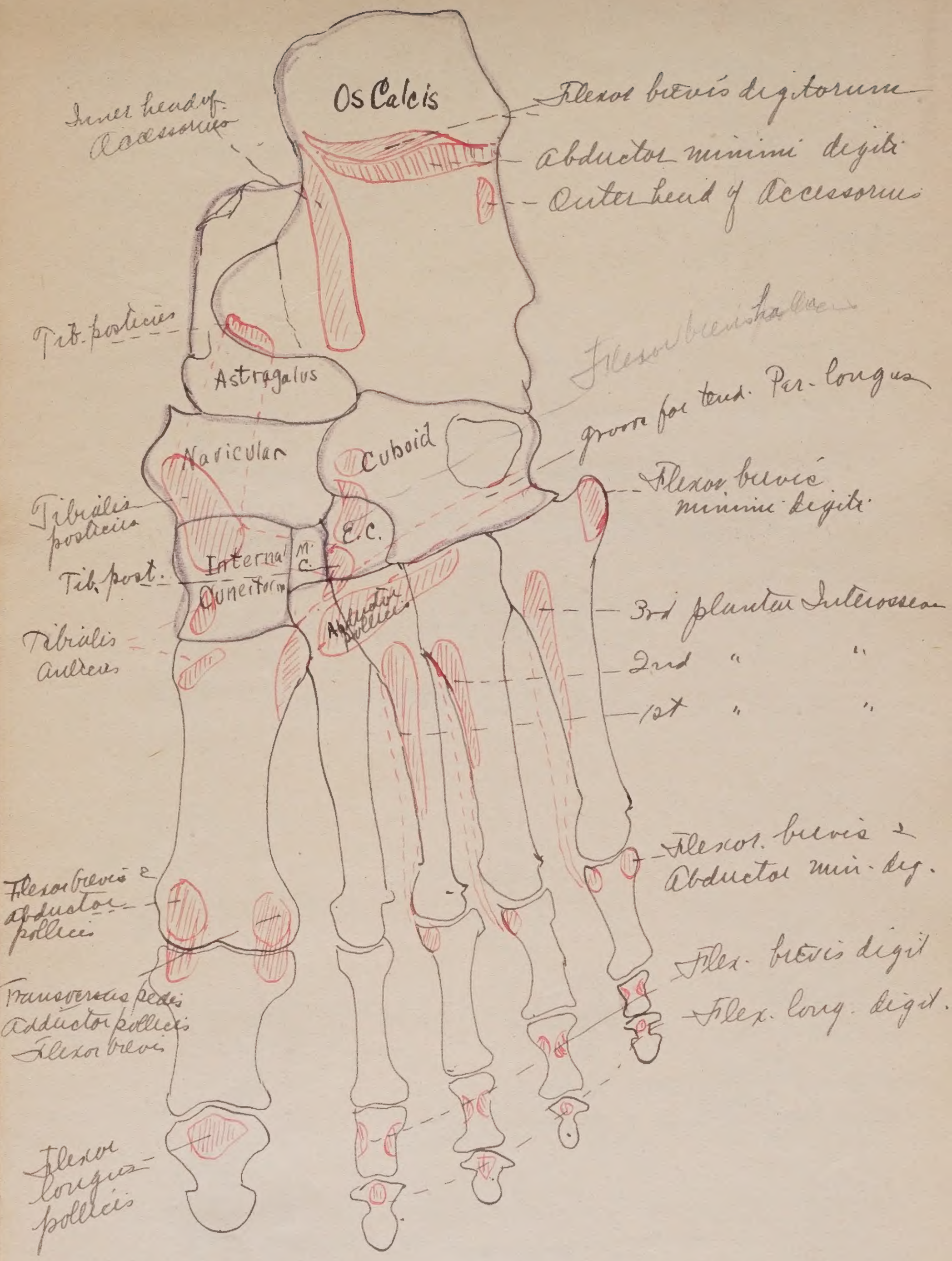
Os Calcis
Inner head of Accessorius
Flexor brevis digitorum
Abductor minimi digiti
Outer head of Accessorius
Tib. posticus
Astragalus
Flexor brevis hallucis
groove for tend. Per. longus
Navicular
Cuboid
Flexor brevis minimi digiti
Tibialis posticus
E.C.
Internal Cuneiform
M.C.
Tib. post.
Adductor pollicis
3rd plantar Interossea
Tibialis anticus
2nd " "
1st " "
Flexor brevis & Abductor min. dig.
Flexor brevis & abductor pollicis
Flex. brevis digit
Transversus pedis
adductor pollicis
Flexor brevis
Flex. long. digit.
Flexor longus pollicis

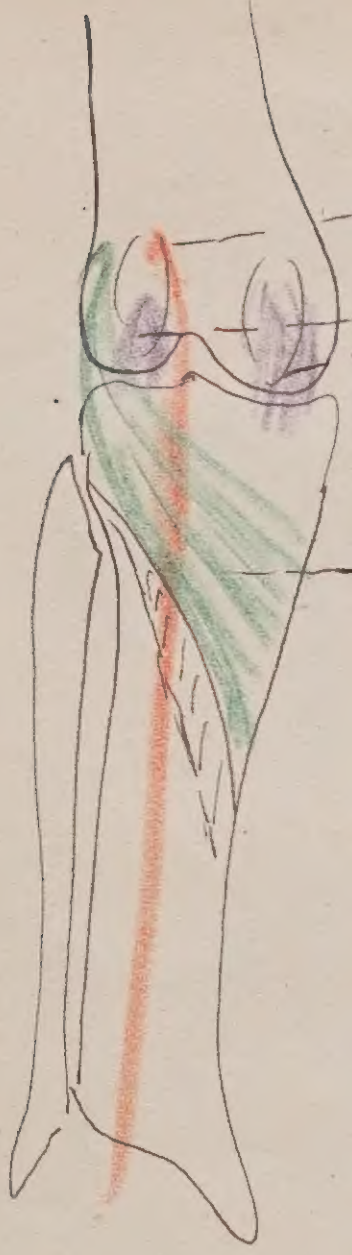

(Covers space between Calcaneum and navicular bone, forming part of an articular facet which supports the astragalus.

Calcaneo-cuboid ligament - from Calcaneum to Cuboid; with a small Calcaneo-navicular (External) lig. form a V-shaped ligament.

Convex anterior End of ~~Navicular~~ Astragalus and
Concave " " " Calcaneum
form Medio-tarsal joint with
Navicular and Cuboid (Important
in Amputations). Joint is Concavo-convex.

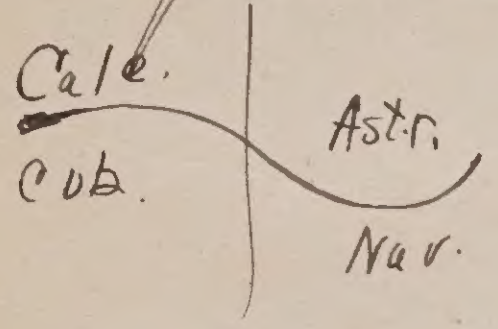

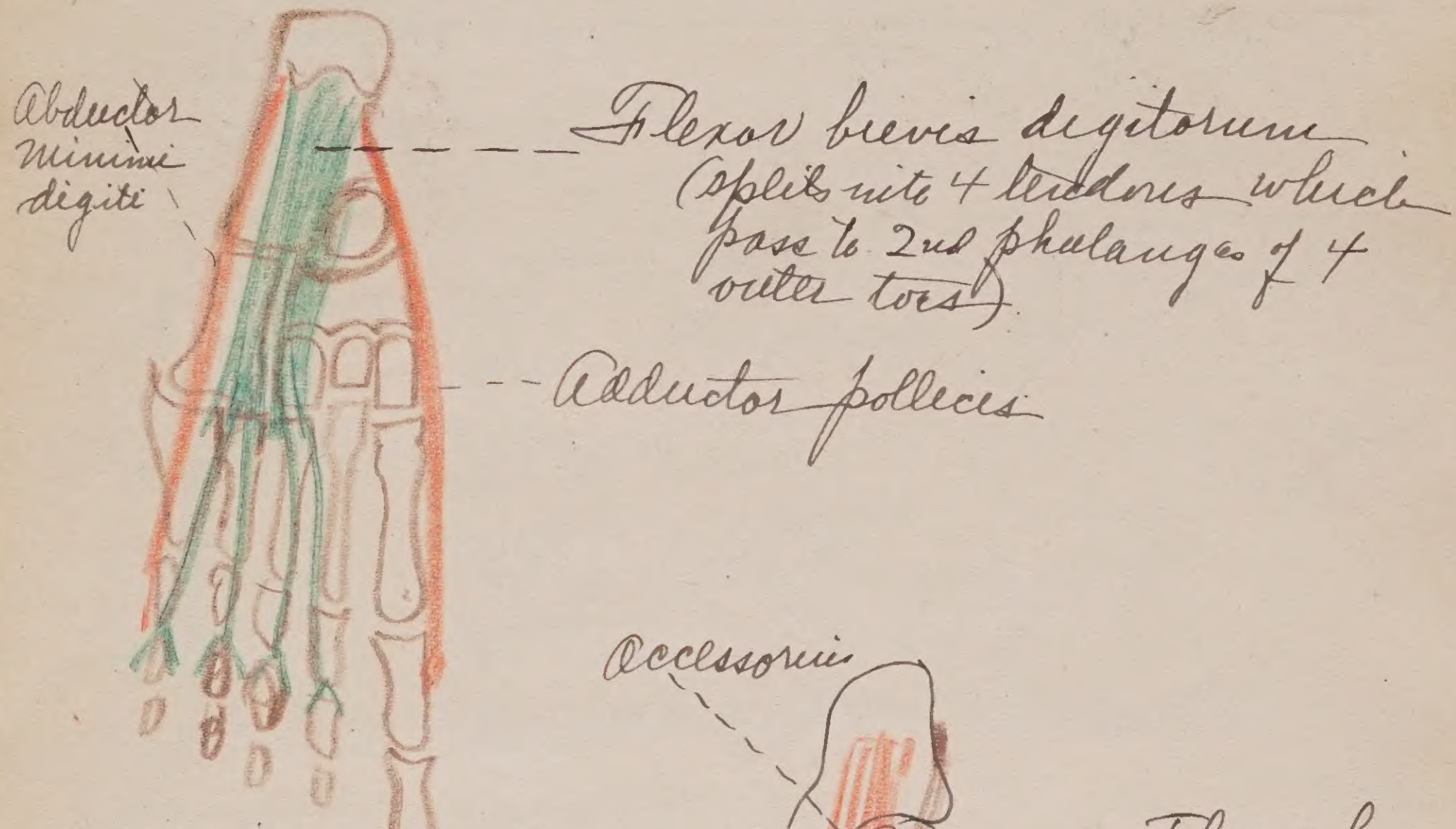

Superficial muscles Plantar Aspect of foot.

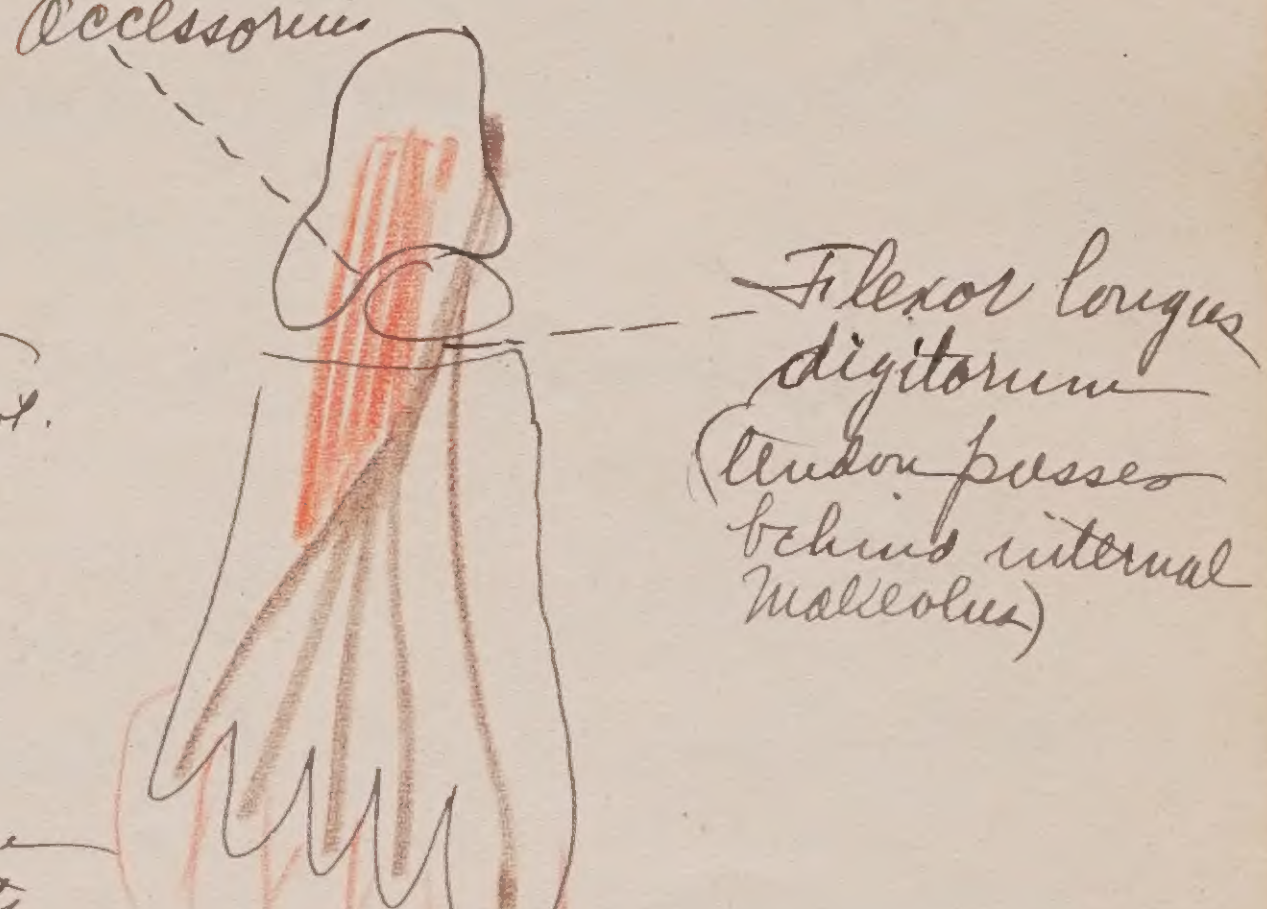

Accessorius arises from Os calcis, inserted into tendons of Flex. long. digitorum, serving to correct the obliquity of these tendons.

Superficial muscles lifted away.

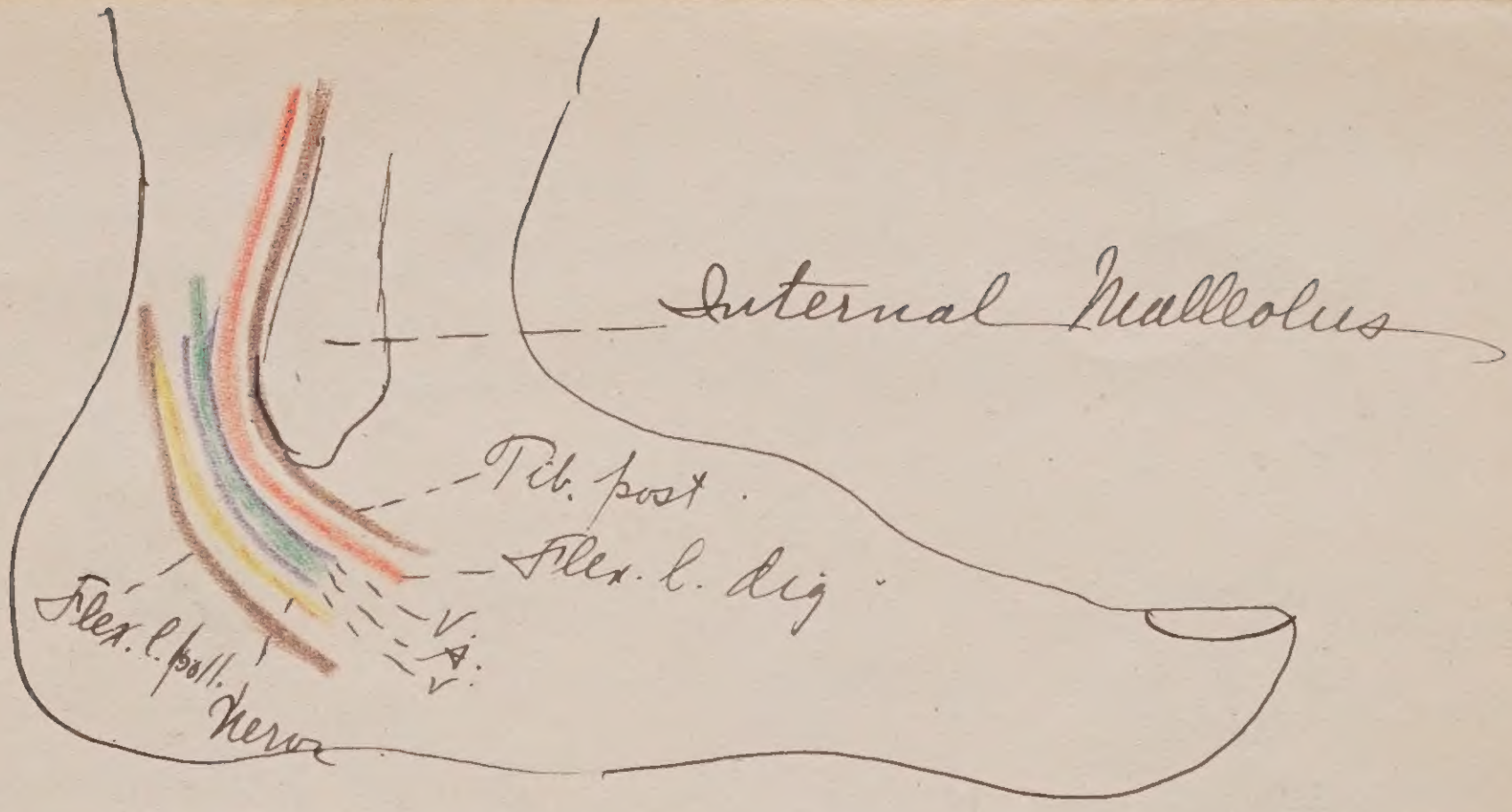

Timothy - Tibialis Posticus
Doth - Flexor longus digitorum
Vex - Vein (Venae comites
All - Artery (Posterior Tibial)
Very - Vein.
Nervous - Nerve (Posterior Tibial)
People - Flexor longus pollicis.

Only structures behind External Malleolus are Peroneus longus and Peroneus brevis.

Joints — Hip, Knee, Ankle

Connected by:—
Vertebrae - Intervertebral discs
Anterior Common Ligaments
Posterior " "
Inter Transverse "
Inter Spinous
Capsular
Ligamenta subflava.

Pelvic Ligaments.
Ant. & Post. Sacro-Iliac Ligaments
Great Sacro-sciatic "
Lesser " "
Poupart's Ligament
Gimbernat's Lig. — a small triangular below inser-tion of Poupart's Lig. Important in operations for strangulated hernia.

Hernia above pubic spine = Inguinal
" below " " = Femoral.

Hip-Joint — Much like shoulder, but deeper. Head of femur fits into acetabulum.
Cotyloid Lig. deepens acetabulum
Ligamentum teres.

Capsular Ligament - includes all.
- origin around entire circum. of acetabular ring. attached around head of femur - Ant. Intertrochanteric line; posteriorly some distance above post. intertrochanteric line.
Also reflected back again along whole neck, as Cervical reflection

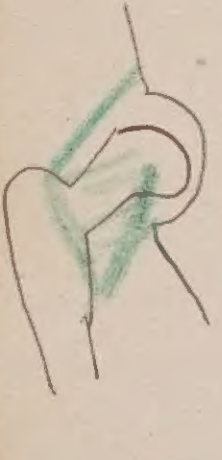

Ilio-femoral Ligament } — From Ant. Inf. Spine of Ilium to Ant. Intertroch. line — is a thickening — sometimes called Y-Ligament, or Bigelow's Ligament.

Insertion is in 2 parts, — to upper end of spiral line (at great trochanter); the other part to lower end of spiral line.

The Other ligaments are internal —

Cotyloid lig. — around acetabulum 3/4 in. deep. Part of Cotyl. lig. bridging over Cotyl. notch is Transverse ligament.

Ligamentum teres — round ligament (a ligament for carrying blood-vessels and nerves, not for strength).

Synovial Membrane — In hip joint comparatively extensive. Lines capsule down to spiral line; then reflected on refl. lig. back to head of femur, to beginning of hyaline cartilage — Covers ligamentum teres.

Fluid within capsule causes knee to be held somewhat flexed and turned outward, to relieve pressure.

Knee-Joint



The cavity of knee-joint extends up 4 or 5 inches above end of femur.

Ligaments of Knee-Joint — — — —

2 groups - External and Internal.

External Group —

<u>Capsular ligament</u> - extends up on front of femur 4 or 5 inches, - and only a slight distance above condyles on sides.

Anterior ligament - tendon of Quadriceps Extensor Muscle.

Posterior ligament - the largest ligament of [illegible].

External - 2 parts - Short and long lateral ligament.

Internal - One long ligament.

<u>Deep Ligaments</u> —

2 Crucial (Cross) Ligaments — — — remnants of partition between the 2 condyles.

Anter. Cruc. L. runs to outer condyle
Poster. " " " " inner "

2 Semi-lunar Fibro-cartelages
Increase depth of sockets - head of tibia.
Not attached to tibia at lower surface - attached by outer surface to capsule.

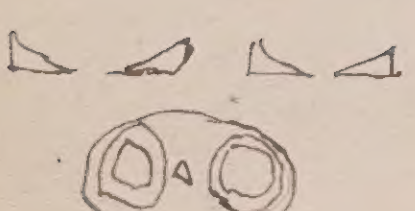

Coronary ligament – from outer edge of semilunar fibro-cartilages, down to tuberosity of tibia.

Transverse ligament – connects semilunar cartilages in front.

Ligamentum mucosum – small ligament, in intercondyloid notch; not strong.

Ligamenta alaria – small ear-like flaps, extending upward and laterally betw. patella and femur.

Synovial membrane of knee-joint is very extensive.

"Floating cartilage" – produces lameness, by getting between articular surfaces of joint

"Water on the knee" – collection of fluid in capsule of joint.

Ankle-joint – a hinge-joint. Between lower extremity of tibia and its malleolus, and ext. malleolus of fibula and upper surface of astragalus and its two lateral facets.

Capsule, – thickened in places, forming.

anterior ligament –
ant. marg. lower ext. tibia to marg. astrag. in front of articular surface.

Posterior Ligament – very thin.
Marg. artic. surf. of tibia – to
Astrag: behind sup. artic facet.

Internal Lateral (Deltoid) Ligament.
Apex and ant. & post. borders of
inner malleolus – to –
ant. fibres to Navicular bone & Inf.
Calc – Navic. lig.
Mid. fibres to Sustentaculum tali
Post. fibres to inner side Astrag.

External Lateral Ligament – 3 parts.
Anterior fasciculus (anterior
astragalo-fibular)
Post. fasciculus – (posterior
astragalo-fibular)
Middle fasciculus (calcaneo-
fibular).

Intercostal Nerves - lower 6 supply muscles of abdomen

12th Intercostal = last Dorsal - sub costal nerve

Lumbar plexus - supplies muscles and skin of anterior part of thigh

Sacral plexus supplies all the rest of leg and ~~thigh~~

Layers of Abdomen

Skin
Superficial fascia
Deep fascia
Ext. Oblique aponeurosis
{Int. Oblique
{Transversalis
Transversalis fascia
peritoneum

these structures are pushed out by the testicle in its descent from the abdominal cavity and form coverings for the same

In Abdomen		In Scrotum
Peritoneum	=	Tunica vaginalis
Transversalis fascia	=	Int. Spermatic fascia or Infundibuliform "
~~Transversalis fascia~~ Internal Oblique	}	Cremaster muscle
External Obl. Aponeurosis	=	Ext. Spermatic fascia
Superficial fascia	=	Dartos
Skin	=	Skin

Inguinal Canal is weakest part of abdominal wall.

Underneath Poupart's ligament following:

Gimbernat ligament
~~Femoral Opening~~
Femoral Vein
~~Femoral Artery~~
Ant. Crural Nerve.
Psoas Magnus Muscle
Iliacus muscle



From Lumbar plexus (Ilio-hypogastric nerve (   )
Ilio-Inguinal " (Ext. Abd. Ring)

Perineum — The region embracing the lower outlet of the pelvic cavity. Made up of 2 triangles—

Posterior Triangle = Rectal Δ

Anterior " = {Genito-urinary or Uro-genital Δ

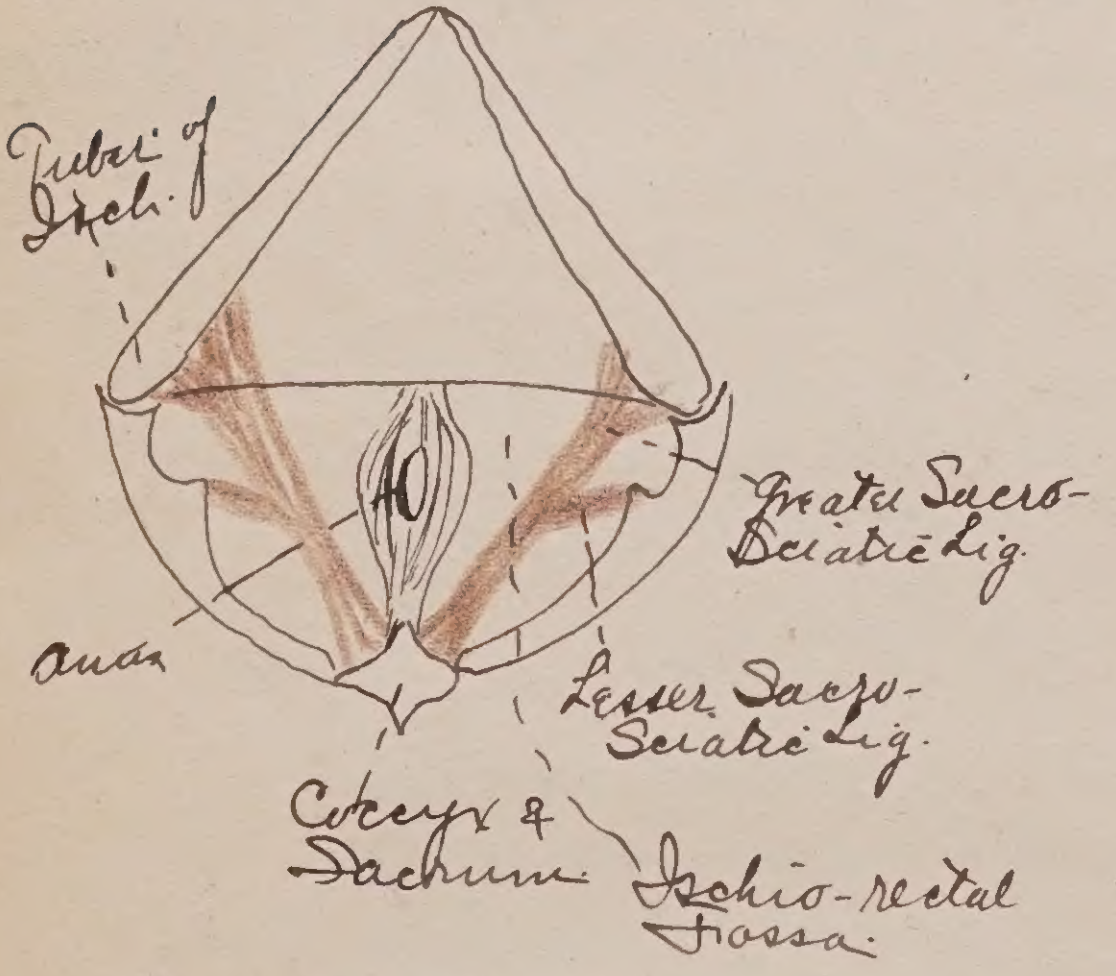

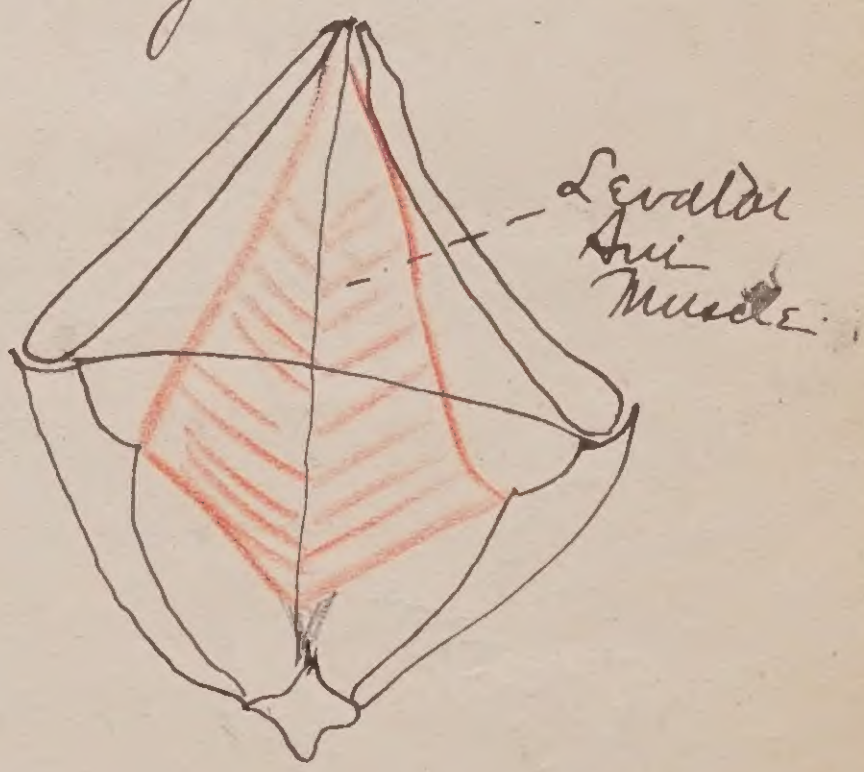

Levator Ani — a large muscle forming floor of abdominal cavity

Bony Attachments {Os Pubis — inner & front; Spine of Ischium; Tip of Coccyx.

Between these points it is attached to fascia — a very thin muscle.

Make vertical section of pelvis

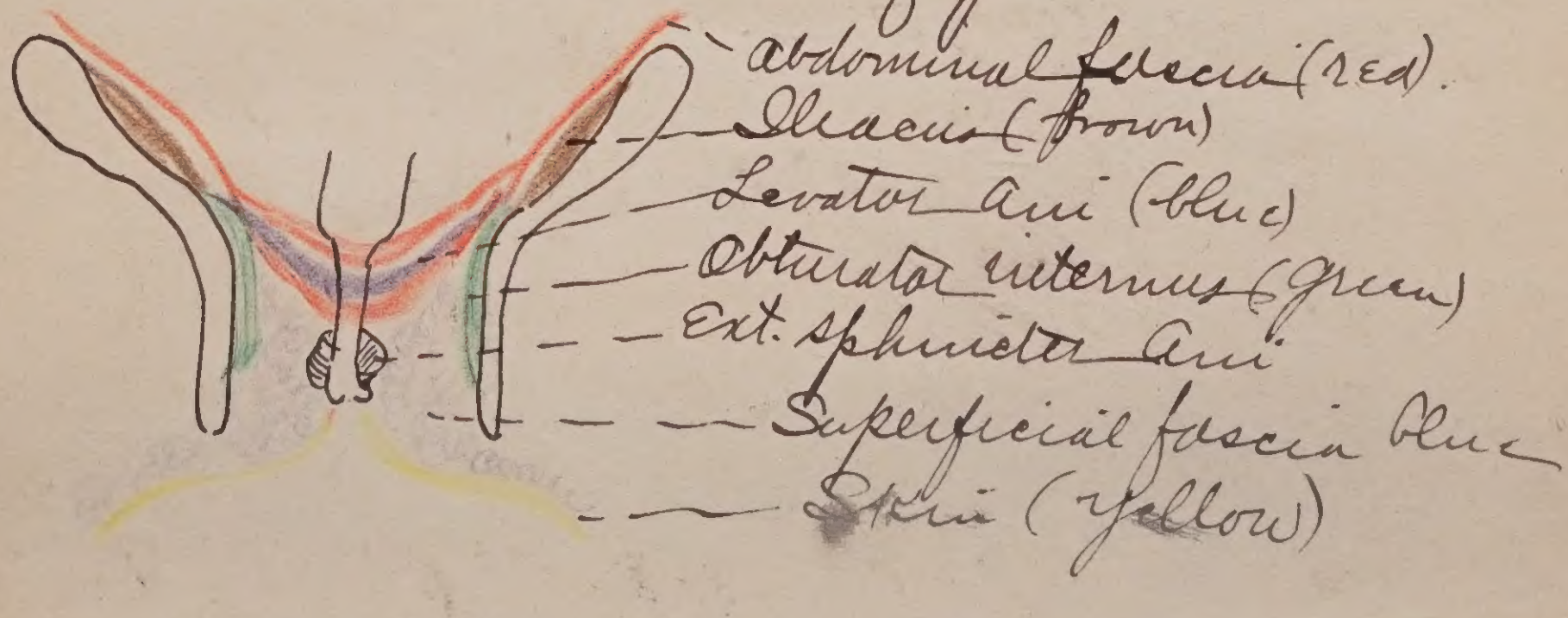

White line – from Os pubis to spine of Ischium – the line where pelvic fascia splits into 3 layers, 2 to enclose Levator ani, and one layer to go over Obturator internus.

Ischio-rectal Fossa – a wedge-shaped fossa – Base covered by integument; apex at white line; inner boundary levator ani & below by termination of anal canal; External boundary fascia covering Obturator internus.

Skin – attached around anal opening. Superficial fascia beneath it and extending deep into ischio-rectal fossa, is very thick, loosely meshed, contains much fat, and has no bony attachments.

Uro-genital Triangle –

Dissect off skin; then superficial layer of superficial fascia (begin to dissect off outside rami of ischia and pubis.

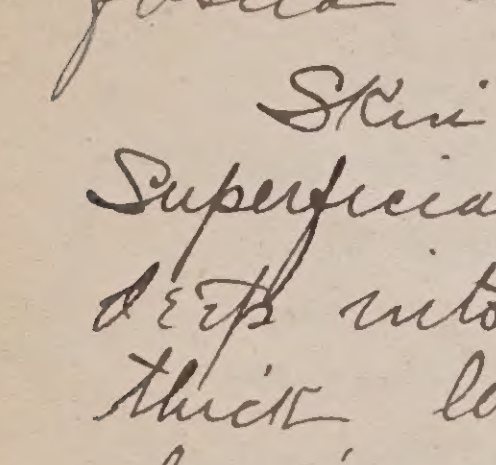

Deep layer of Superficial fascia – a very thin layer, called Colles Fascia; loses itself in deep layer covering Levator ani muscle, being carried also around penis to abdominal wall.



In Extravasation of urine, the urine may pass between the layers of fascia around penis to abdominal wall.

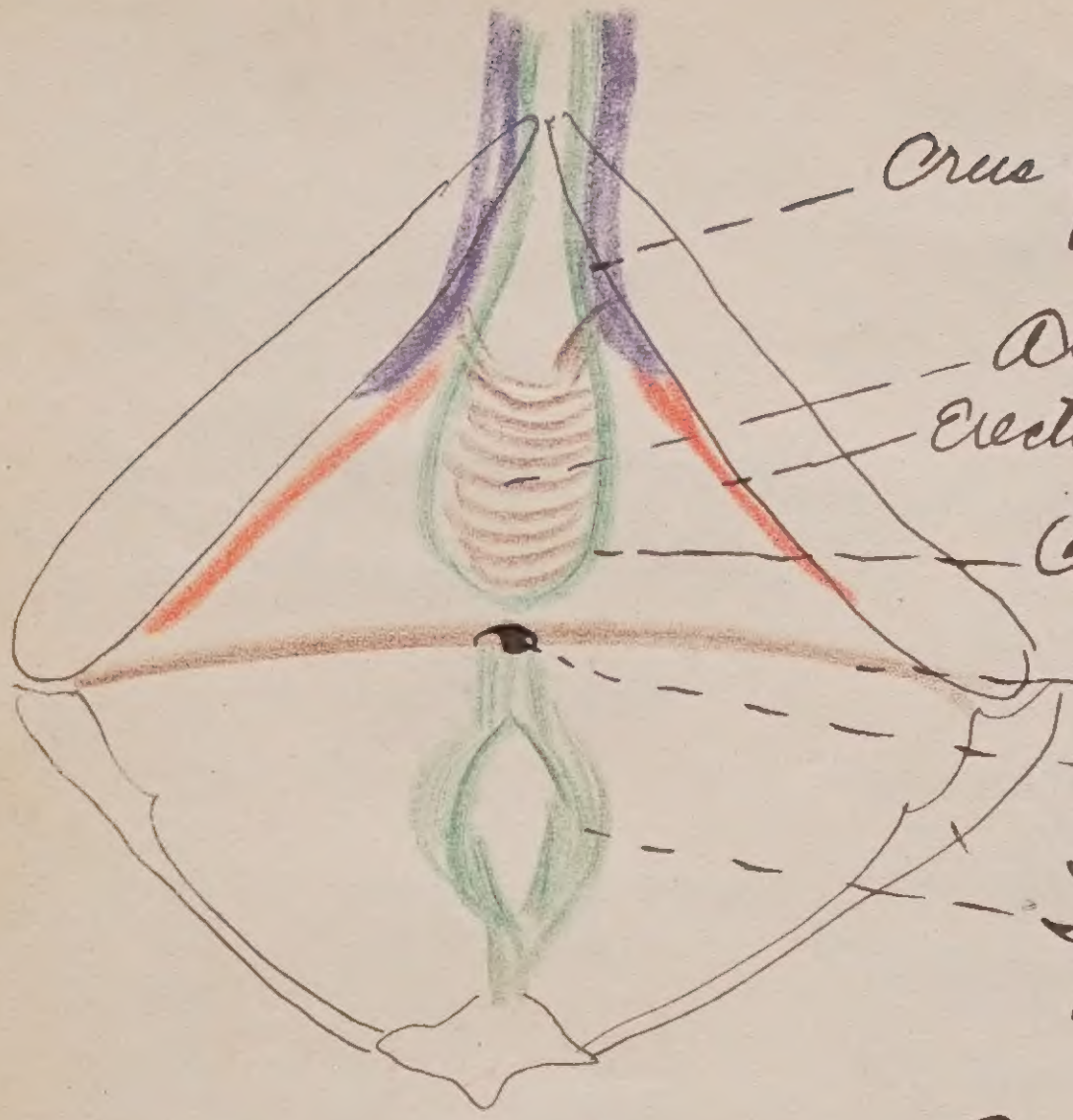

Accelerator Urinae (Bulbo-cavernous) Muscle forces out residual urine. Attached on each side to Corpora cavernosa; passing around bulbus spongiosum

Anterior layer of Triangular ligament - between Bulbus spongiosum, Erector penis and Transversus perinei.

Triangular ligament - Colles ligament splits in region of Uro-genital triangle





The Triangular ligament forms a double layer attached from symphysis pubis down spine of Ischium, around membranous

portion of Urethra. The Compressor Urethrae muscle is in Triangular Lig.

The Great Artery and Nerve of this region are the Internal Pudic Artery and Nerve.

Internal Pudic Artery - branch from Internal Iliac, enters Ischio-rectal fossa, running along its side wall giving off Inferior Haemorrhoidal arteries.

Inferior Haemorrhoidal Veins collect blood from region of rectal triangle.



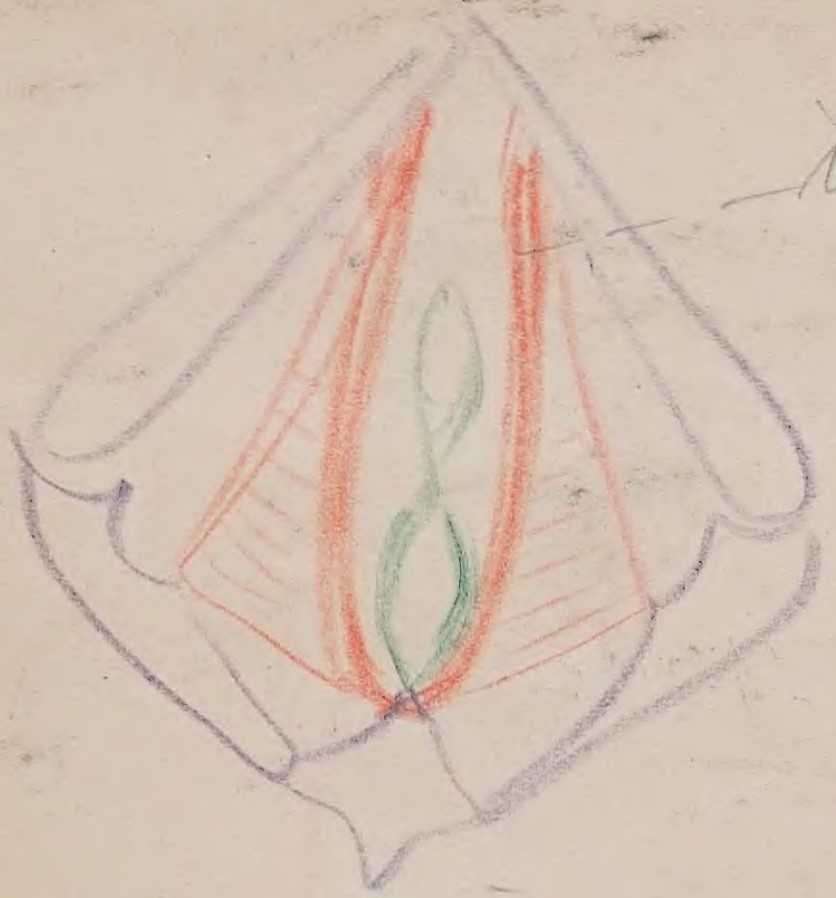

thickened portion of
Levator Ani Muscle
in female —
Pubo-coccygeal
Ligament. Act
as supporter of
female genitalia.

When torn may allow prolapsus
of the uterus

Surg Inguinal Canal
Arteries.
Aorta - from bifurcation.
Common Iliac
External "
Femoral.

Popliteal
Ant. & Post. Tibial (Linear Guide
& branches
Course of artery (Continued)
Lumbar plexus

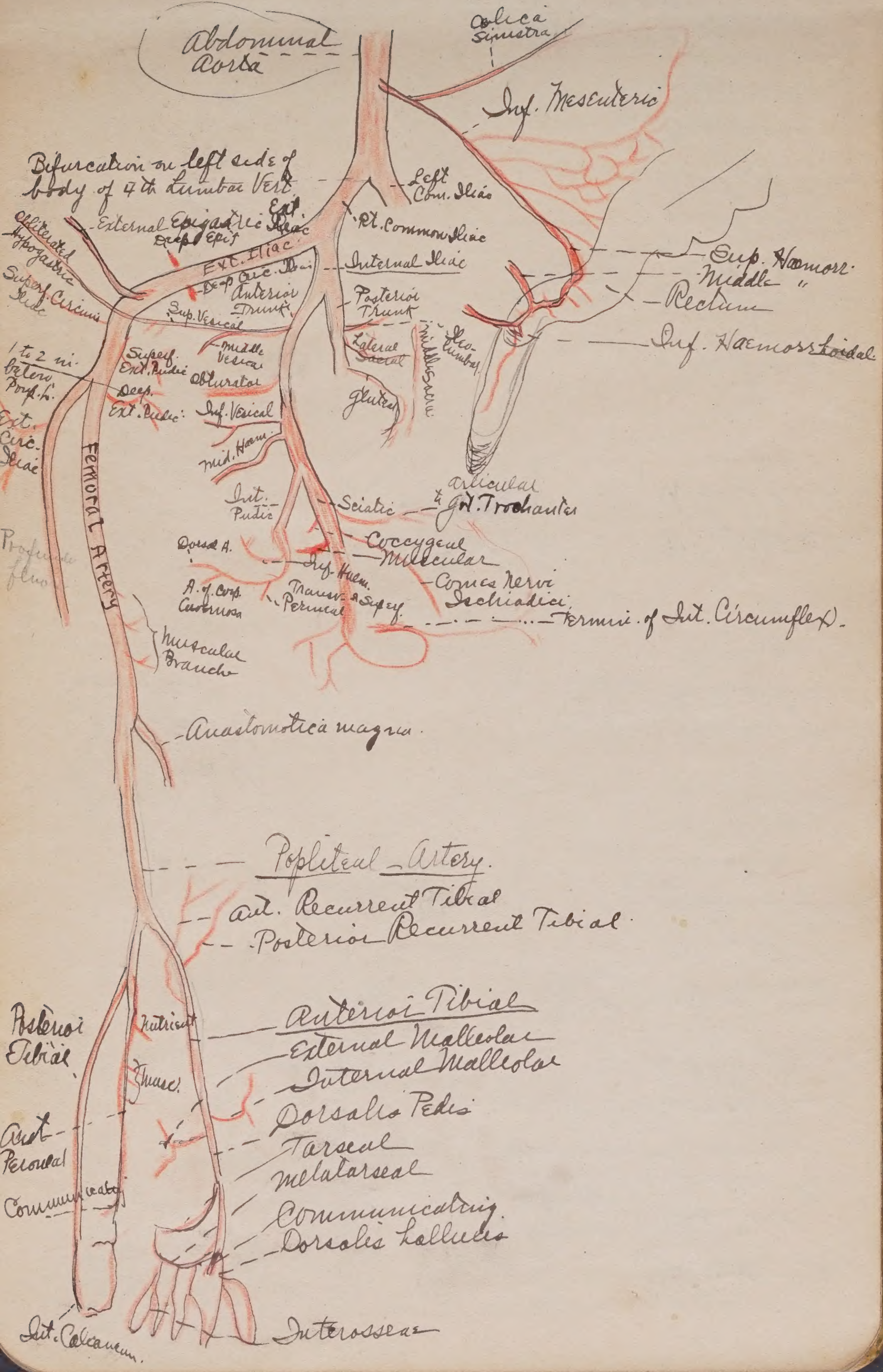

Abdominal Aorta
Colica Sinistra
Inf. Mesenteric
Bifurcation on left side of body of 4th Lumbar Vert.
Left Com. Iliac
Ext. Iliac
External Epigastric
Deep Epig
Obliterated Hypogastric
Rt. Common Iliac
Ext. Iliac
Internal Iliac
Superf. Circum. Iliac
Deep Circ. Iliac
Anterior Trunk
Posterior Trunk
Sup. Vesical
Sup. Haemorr.
Middle "
Rectum
Inf. Haemorrhoidal
Middle Vesical
Superf. Ext. Pudic
Lateral Sacral
Ileo-lumbar
Middle Sacra
1 to 2 in. below Poup. L.
Deep Ext. Pudic
Obturator
Gluteal
Ext. Circ. Iliac
Inf. Vesical
Femoral Artery
mid. Haem.
Int. Pudic
Sciatic
articular & Gr. Trochanter
Coccygeal
Profunda Femo
Dorsal A.
Inf. Haem.
Muscular
Comes Nervi Ischiadici
A. of Corp. Cavernosa
Transv. & Superf. Perineal
Termini of Int. Circumflex
Muscular Branches
Anastomotica magna
Popliteal Artery
Ant. Recurrent Tibial
Posterior Recurrent Tibial
Posterior Tibial
Nutrient
Anterior Tibial
External Malleolar
Internal Malleolar
Muscl.
Dorsalis Pedis
Ant. Peroneal
Tarsal
Metatarsal
Communicating
Communicating
Dorsalis hallucis
Int. Calcaneum
Interosseae

- Descending Aorta
  - Inferior Mesenteric
    - Colica sinistra
    - Sigmoid
    - Superior Haem.
  - Right (or Left) Common Iliac
    - Internal Iliac
      - Anterior Trunk
        - Superior Vesical
        - Middle "
        - Inferior "
        - Mid. Haemorrh.
        - Obturator
        - Internal Pudic
        - Sciatic
        - ♀ {Uterine, Vaginal}
      - Posterior Trunk
        - Ilio-lumbar
        - Lateral Sacral
        - Gluteal
    - External Iliac
      - Deep Epigastric
      - Deep Circumflex Iliac
    - Superficial Femoral
      - Superficial Epigastric
      - Superf. Circumflex Iliac
      - Superf. Ext. Pudic
      - Deep Ext. Pudic
      - Muscular
      - Anastomotica magna
    - Profunda Femoris
      - Ext. Circumflex
      - Int. "

- Popliteal
  - Muscular
    - Superior
    - Inferior or Sural
  - Cutaneous
  - Superior Int. Articular
  - " Ext. "
  - Azygos "
  - Inf. Int "
  - Inf. Ext. "
- Anterior Tibial
  - Posterior Recurrent Tibial
  - Superior Fibular
  - Ant. Recurrent Tibial
  - Muscular
  - Internal Malleolar
  - External Malleolar
  - Dorsalis Pedis
    - Tarsal
    - Metatarsal (Inter-osseous)
    - Dorsalis Hallucis
    - Communicating
- Posterior Tibial
  - Nutrient
  - Muscular
  - Communicating
  - Int. Calcanean
  - Peroneal
    - Muscular
    - Nutrient
    - Anterior Peroneal
    - Communicating
    - Posterior Peroneal
    - External Calcanean
  - Internal Plantar
  - External Plantar
    - Post. Perforating
    - Digital – Ant. Perforating.

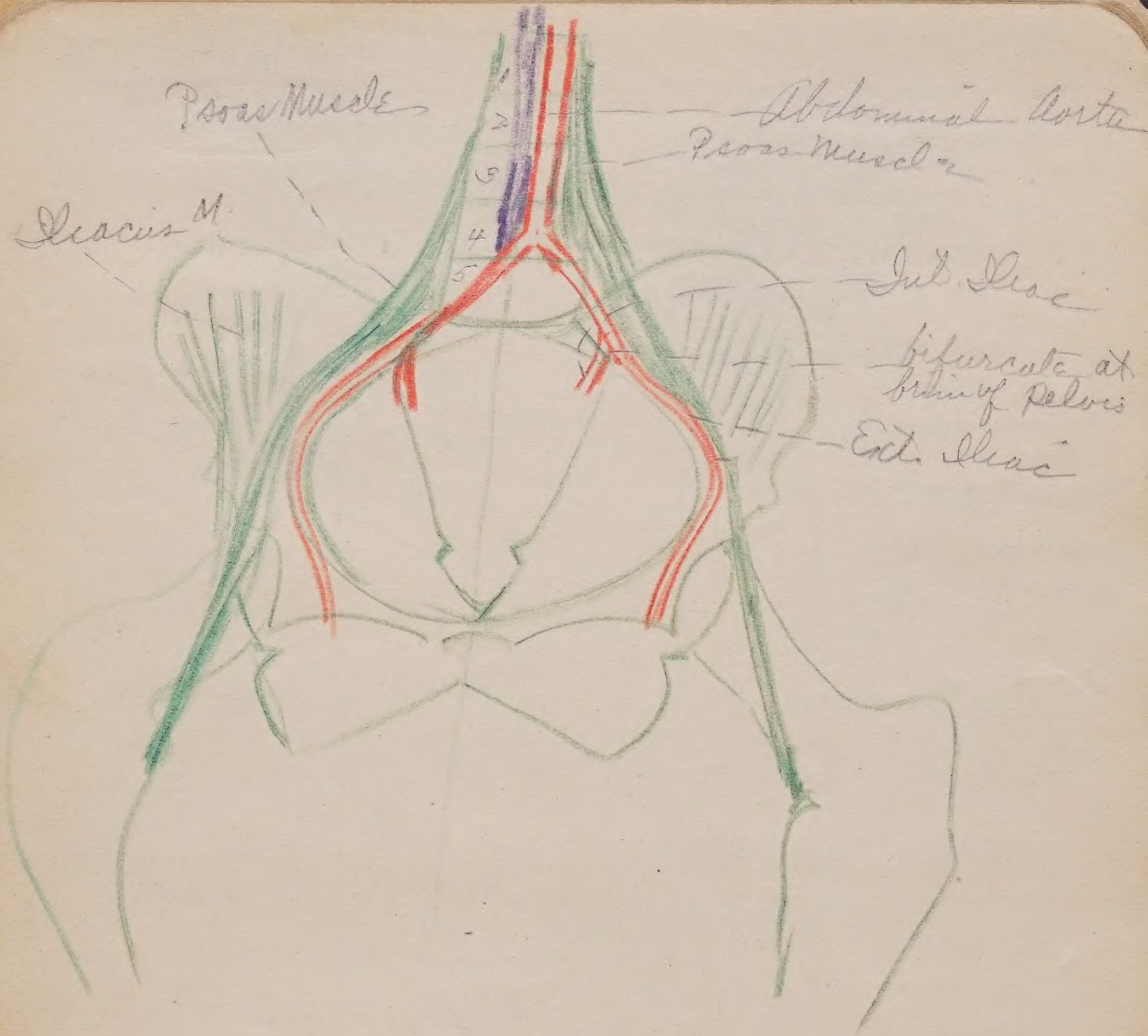

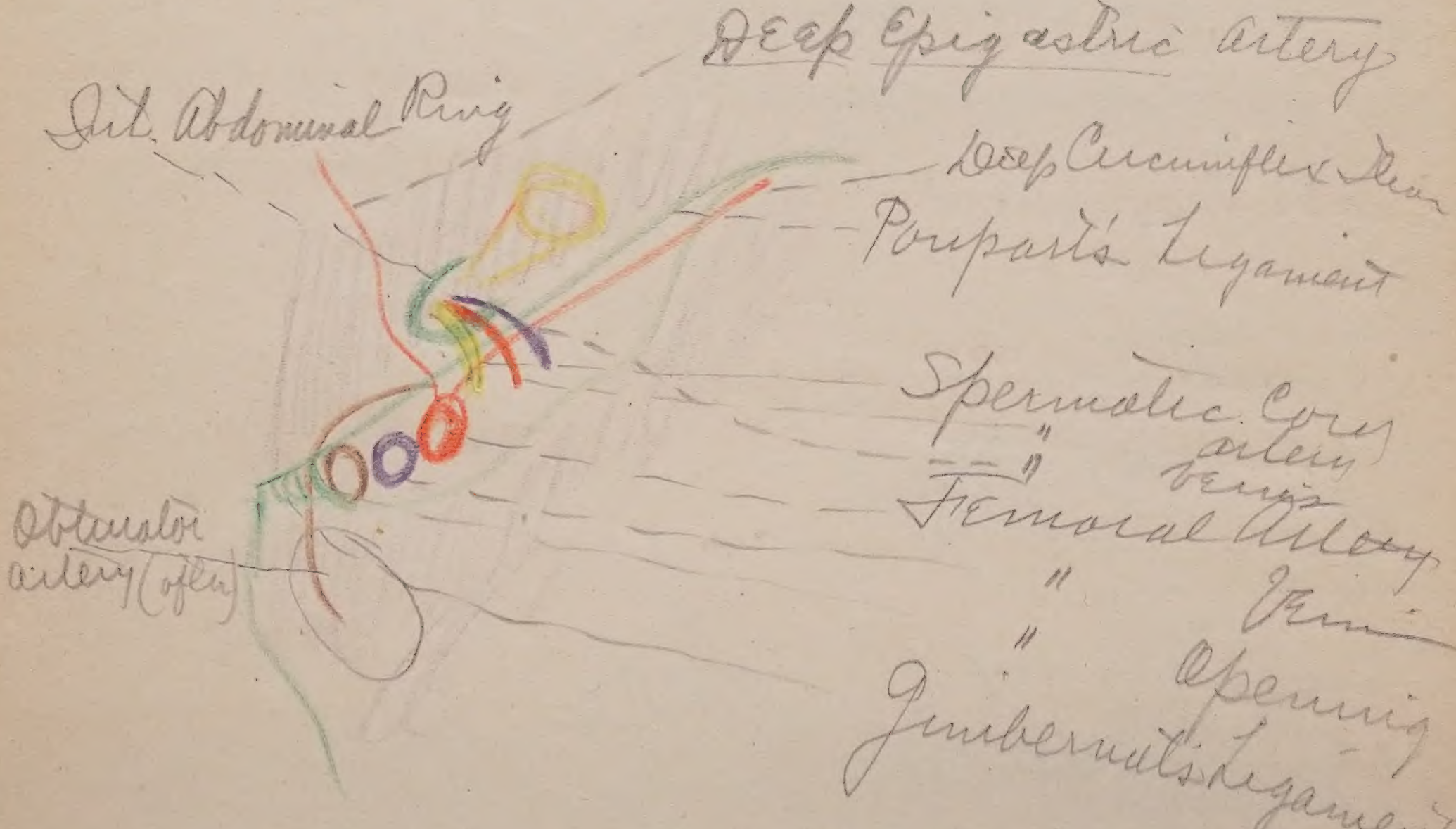

View from Interior of Pelvis

Deep Epigastric artery — Surface marking — Mid-Poupart point up toward umbilicus. Anastomoses with Internal Mammary — longest anastomosis in the body.

Deep Epigastric Artery very important in hernia. External or Internal oblique hernia according to relation to Deep Epig. Artery.
Deep Circumflex artery runs along within line of Poupart's ligament to Anterior Superior Spine of Ilium

Obturator (in about 1 out of 3 cases) comes off from deep Epigastric.
Usually from Anterior Trunk of Internal Iliac
In Femoral hernia, Gimbernat's ligament usually causes strangulation (take it for granted that Obturator artery passes along inner side of G's ligament

Venae Comites — found in hand, forearm, and arm up to axilla.
In leg, Venae Comites extend up as far as popliteal space — when they unite as popliteal Vein

In Scarpa's △

In Hunter's Canal



In Popliteal Space

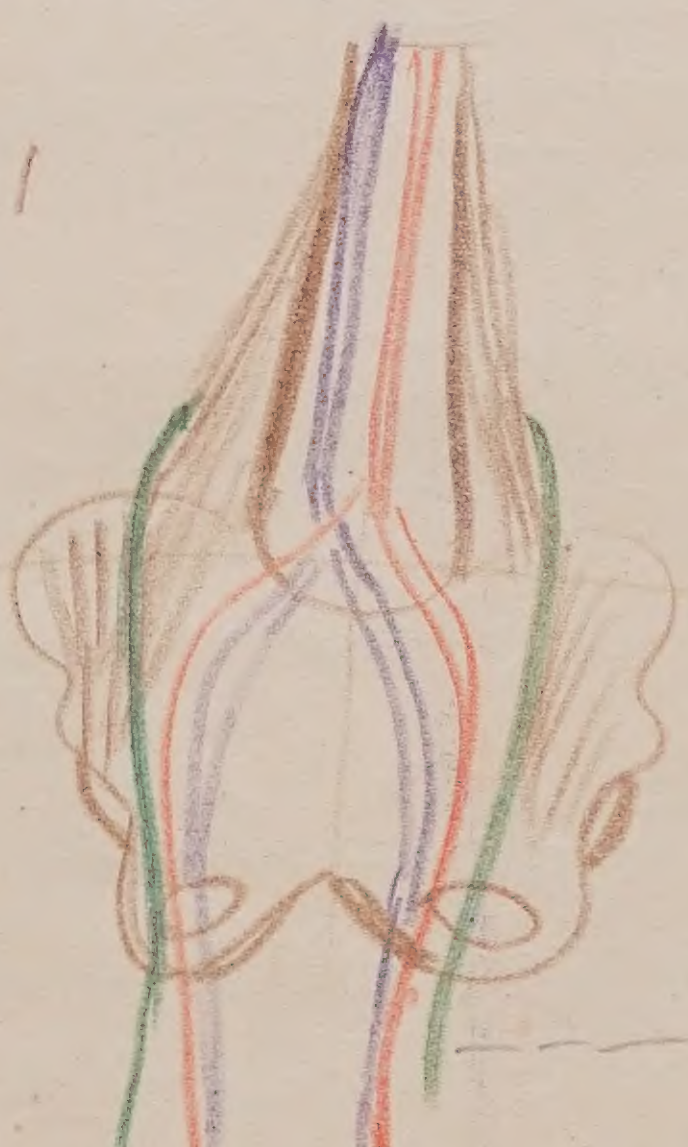

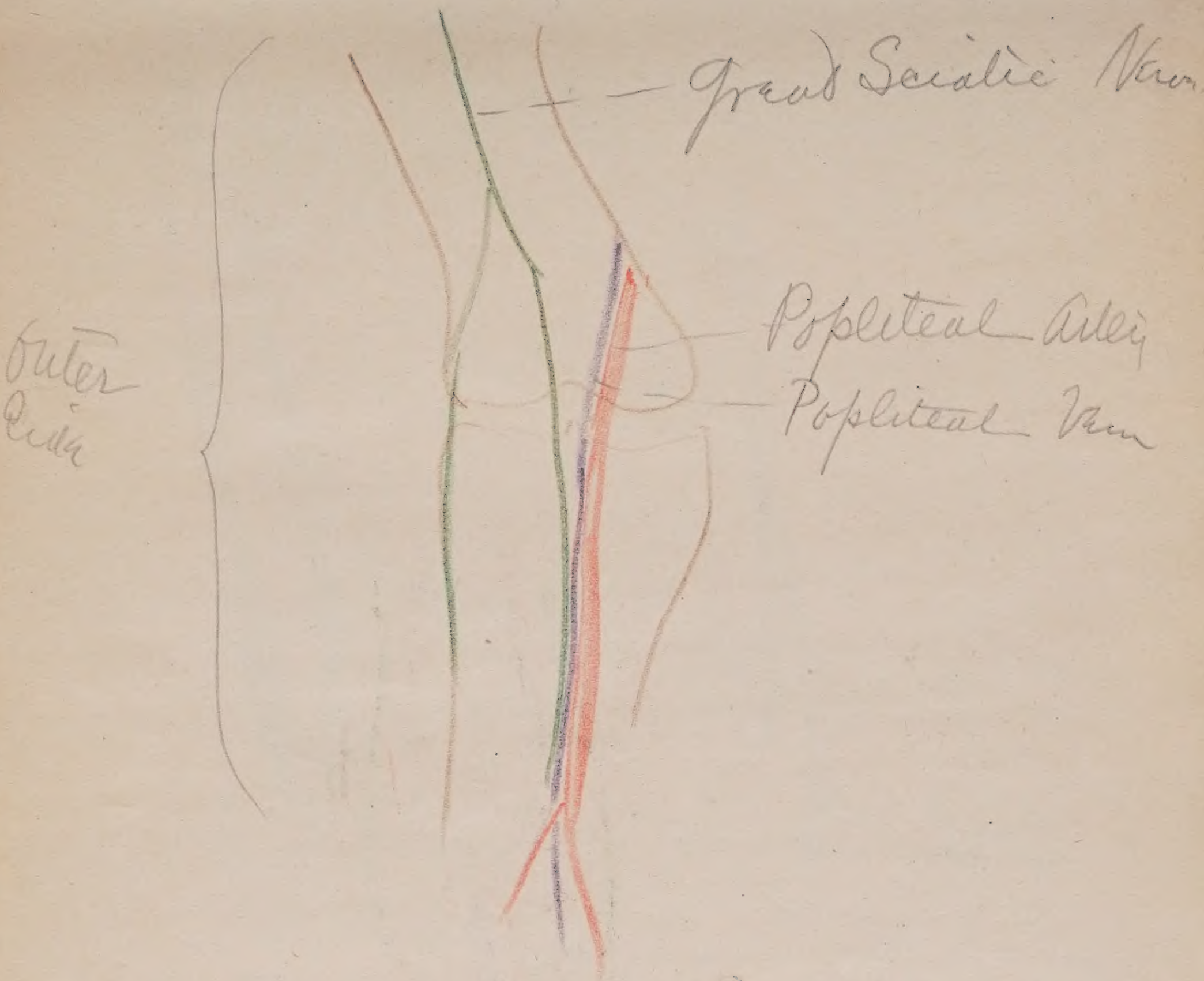
Great Sciatic Nerve
Popliteal Artery
Popliteal Vein
Outer side

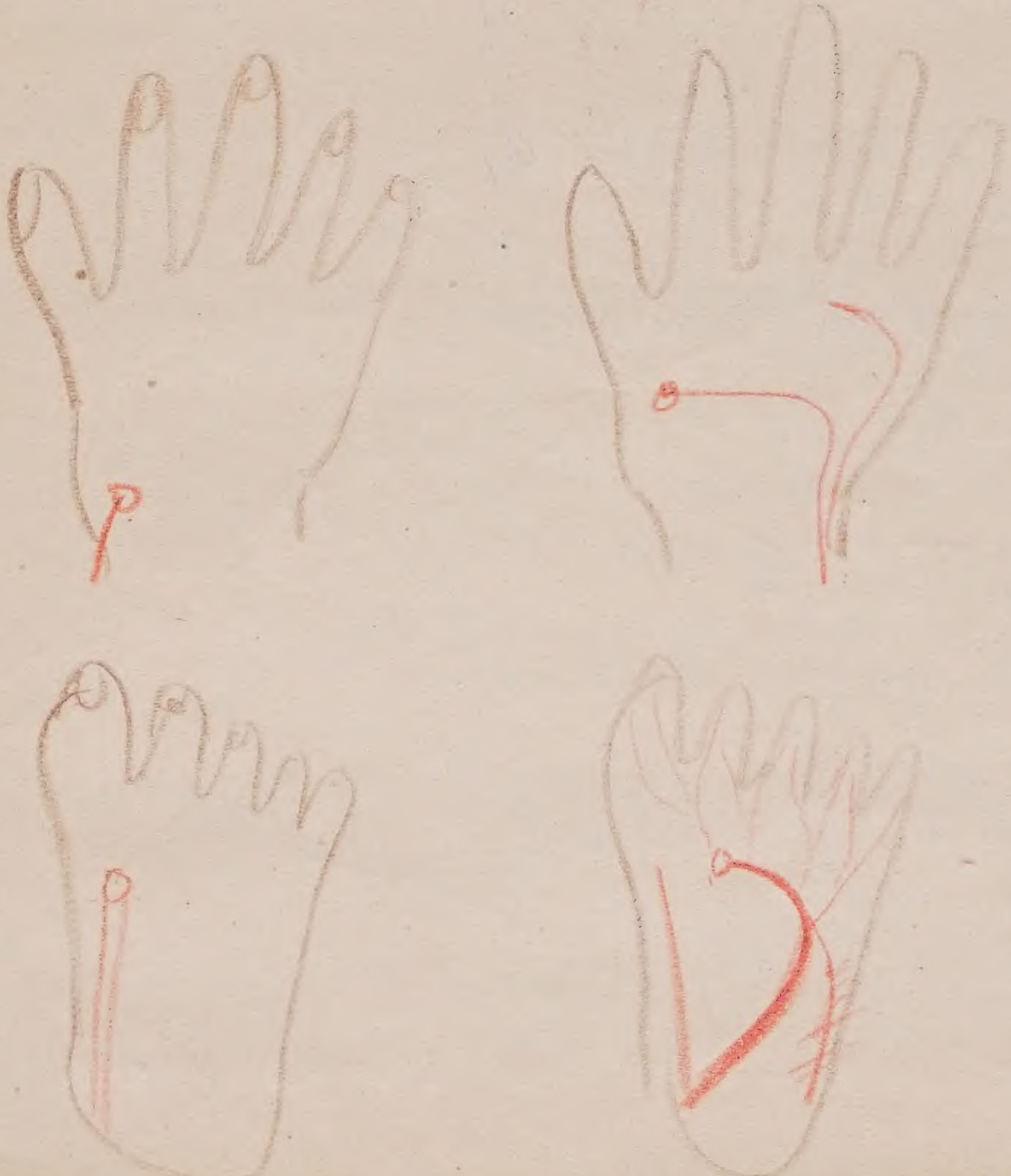

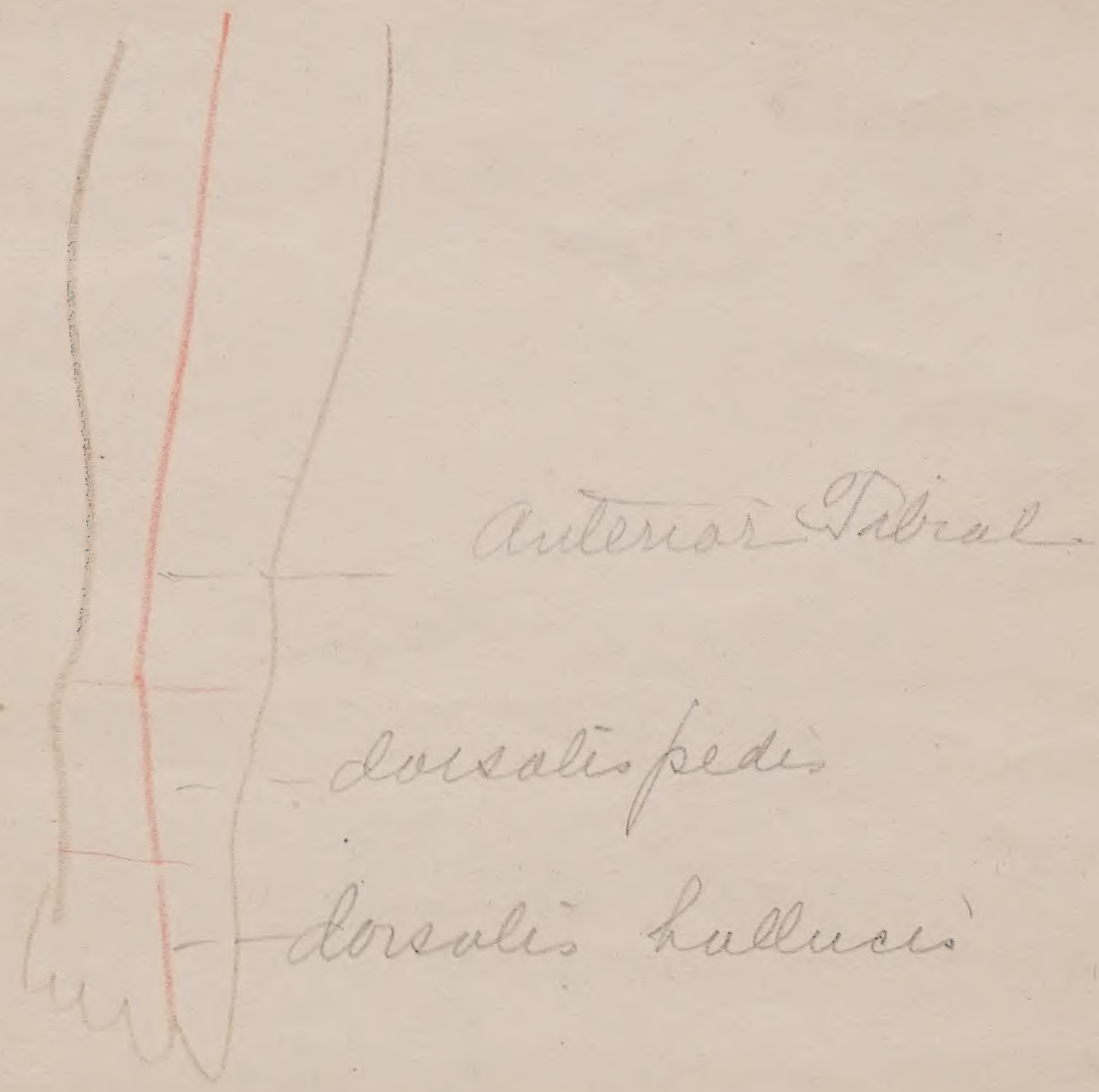
anterior Tibial
dorsalis pedis
dorsalis hallucis

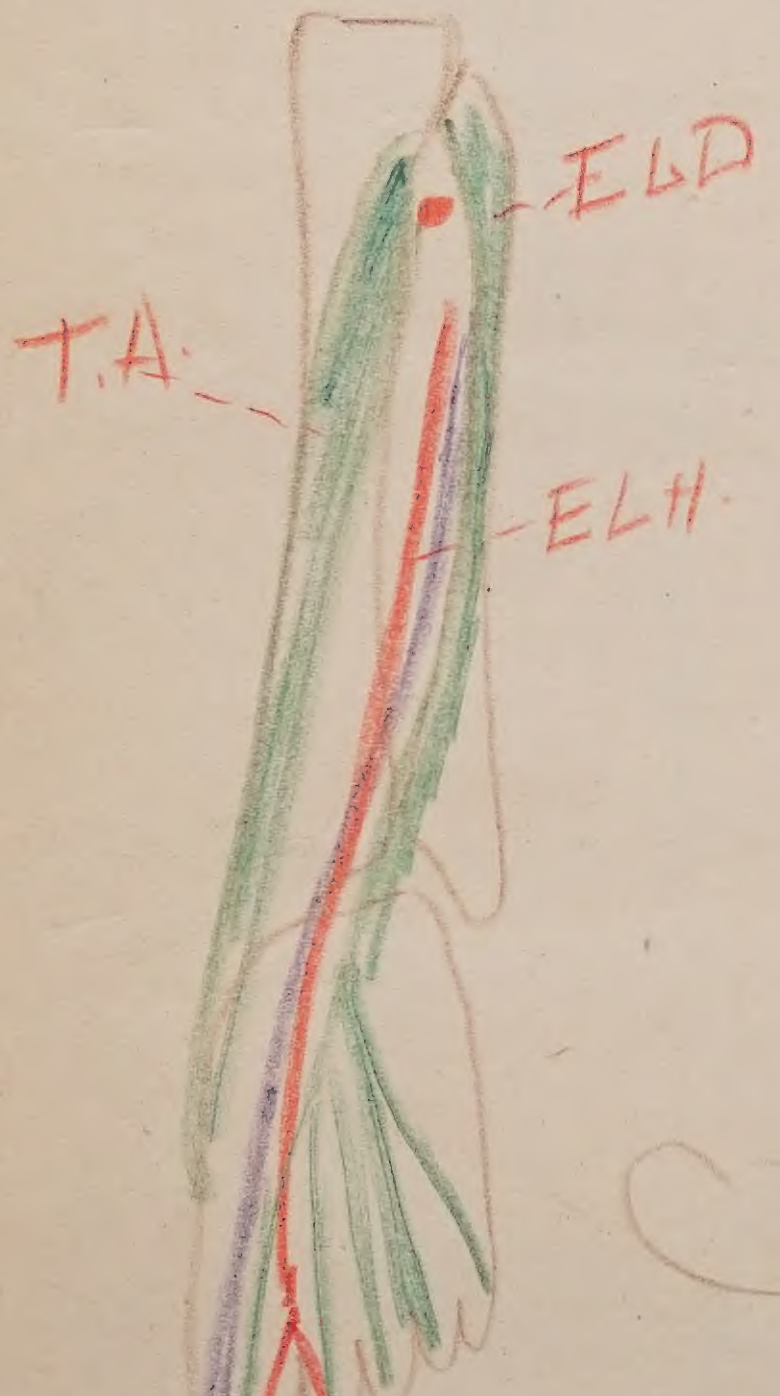
ELD
T.A.
ELH

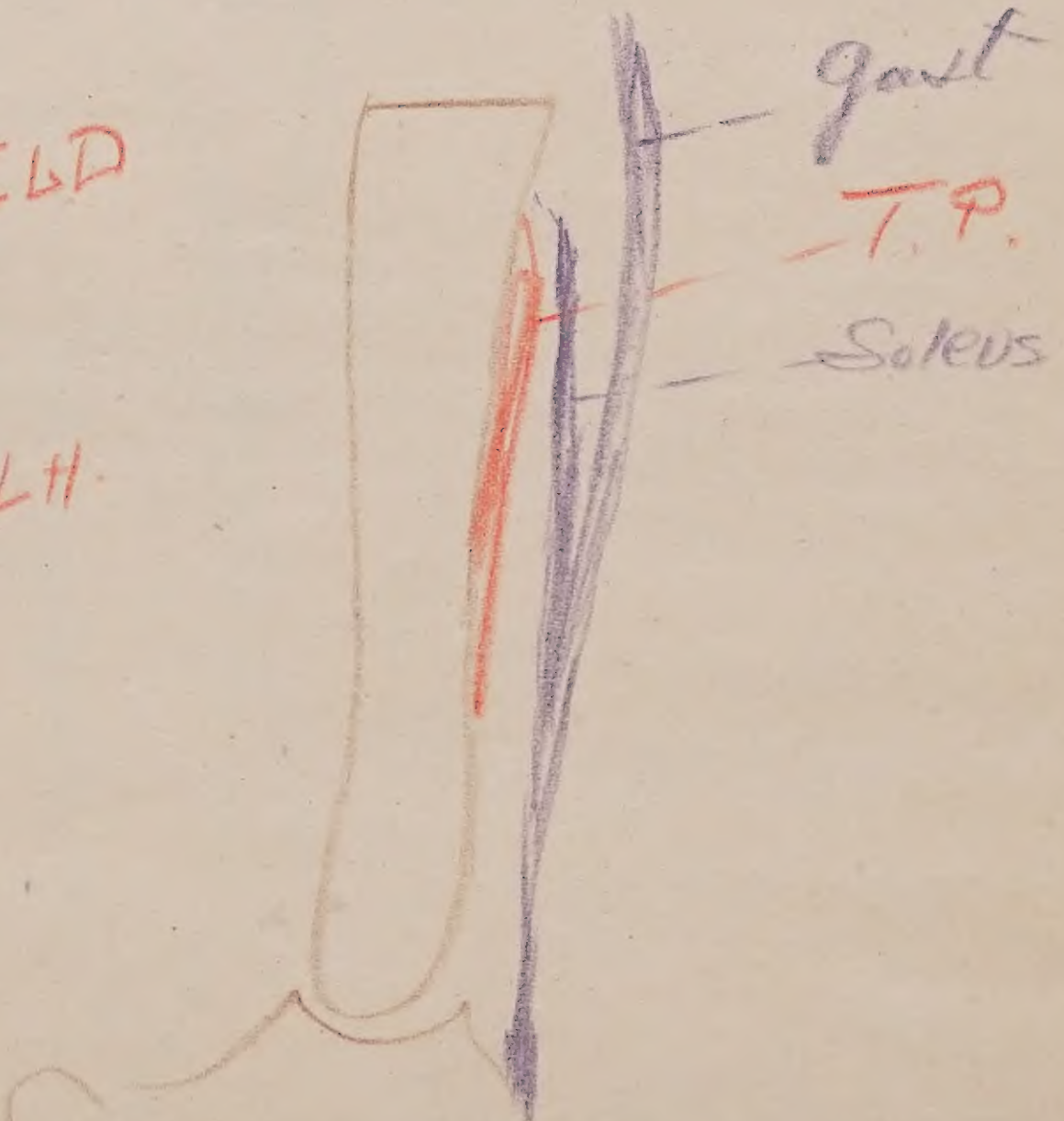
gast
T.P.
Soleus



Nerves are generally superficial to arteries (guarding them) - along ribs



Major portion of 1st thoracic goes to form the Brachial plexus

1st (sometimes) and 2nd (always) - give to arm = Inter-costo-humeral nerve

3rd sometimes

Nerves from 7th to 12th Dorsal.

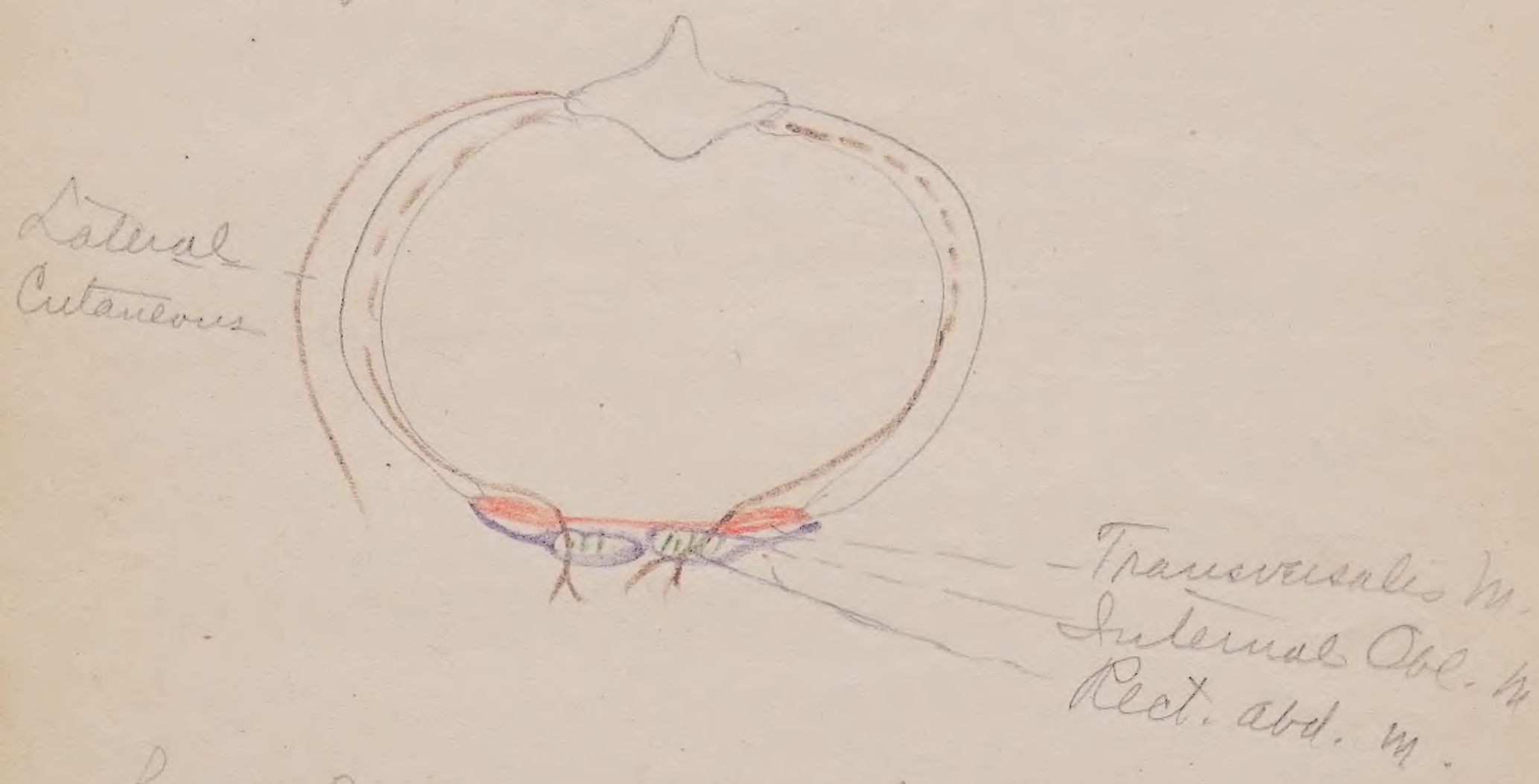

Lower Intercostal Nerves also supply abdominal muscles. Do not anastomose with each other (Except 1st and 2nd.)

12th Intercostal (or Subcostal Nerve) (together with Ilio-hypogastric Ilio-Inguinal) passes over kidney, resting upon it.
Its lateral cutaneous branch is very peculiar. - runs down betw. Transv. & Int. Obl. & crest of Ilium, and courses down in region of great trochanter

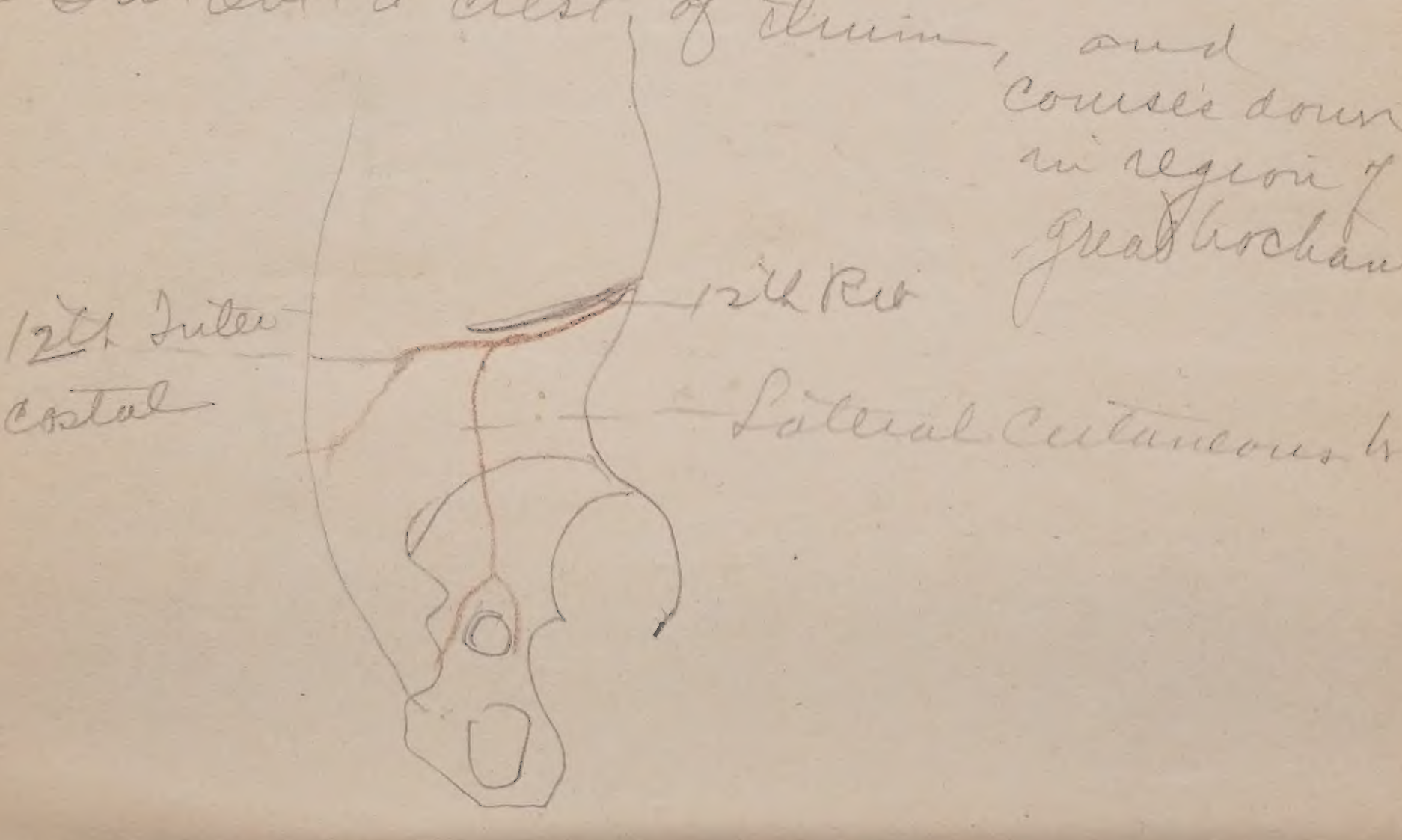

{Lumbar Plexus –
Sacral Plexus –
Coccygeal Plexus –} sometimes divided differently

Lumbar Plexus – nerves arising from lumbar vertebrae – in substance of Psoas muscle

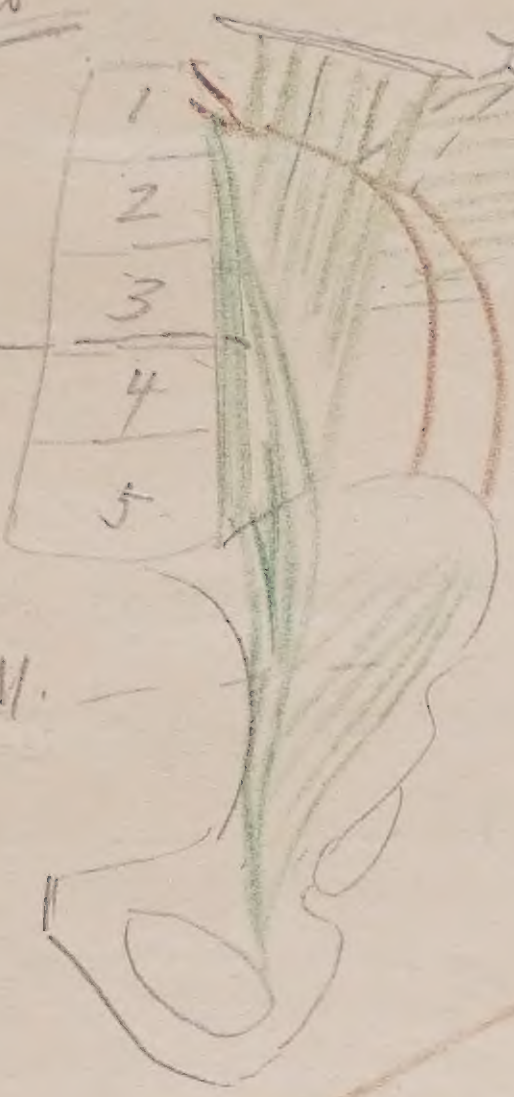

12D
1L
2L
3L
4L

(Ilio-hypogastric 12D + 1L.
Ilio-Inguinal
Genito-Crural (1+2)
Extern. Cutaneous (2+3)
Anterior Crural (2+3+4)
Obturator (2+3+4).
Accessory Obturator (3+4) rarely present)

(Consonant between 2 vowels)
4L (Ext Cut) (Genito Crural) Ant Crural.
L5 – Lumbo-Sacral Cord.
S1
S2
S3
S4
S5
C1

Muscular
Superior Gluteal
Inferior Gluteal
Greater Sciatic
Lesser Sciatic
Perforating Cutaneous
Internal Pudic

Sacral Plexus

Coccygeal Plexus
Supplies Levator Ani + Ext. Sphincter

Ilio-hypogastric runs forward across crest of Ilium, pierces transversalis, and finally become cutaneous just above (1½ in) above Int. abdominal ring

Ilio-Inguinal passes between Transversalis and Int. Oblique, passes through Inguinal Canal - supplies scrotum ♂ and Labia majora in ♀. - Situated beneath aponeurosis of Ext. Oblique in Inguinal Canal.

Genito-Crural-

~~anterior~~ Crural N. branch runs under Poup. lig. with femoral artery & anterior portion of thigh. Genital branch - supplies principally Cremaster muscle, and also skin of scrotum (crossed by the ureter). - Symptom of stone in ureter is retraction of testes).

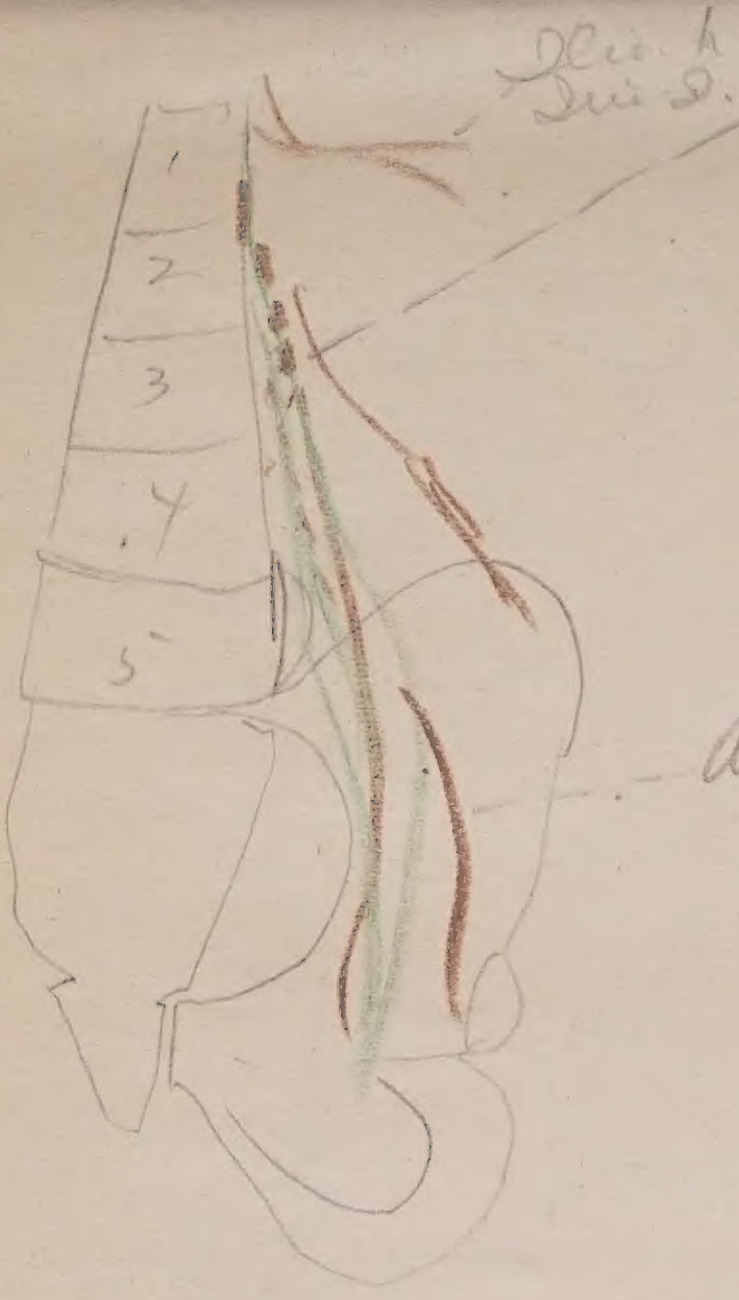

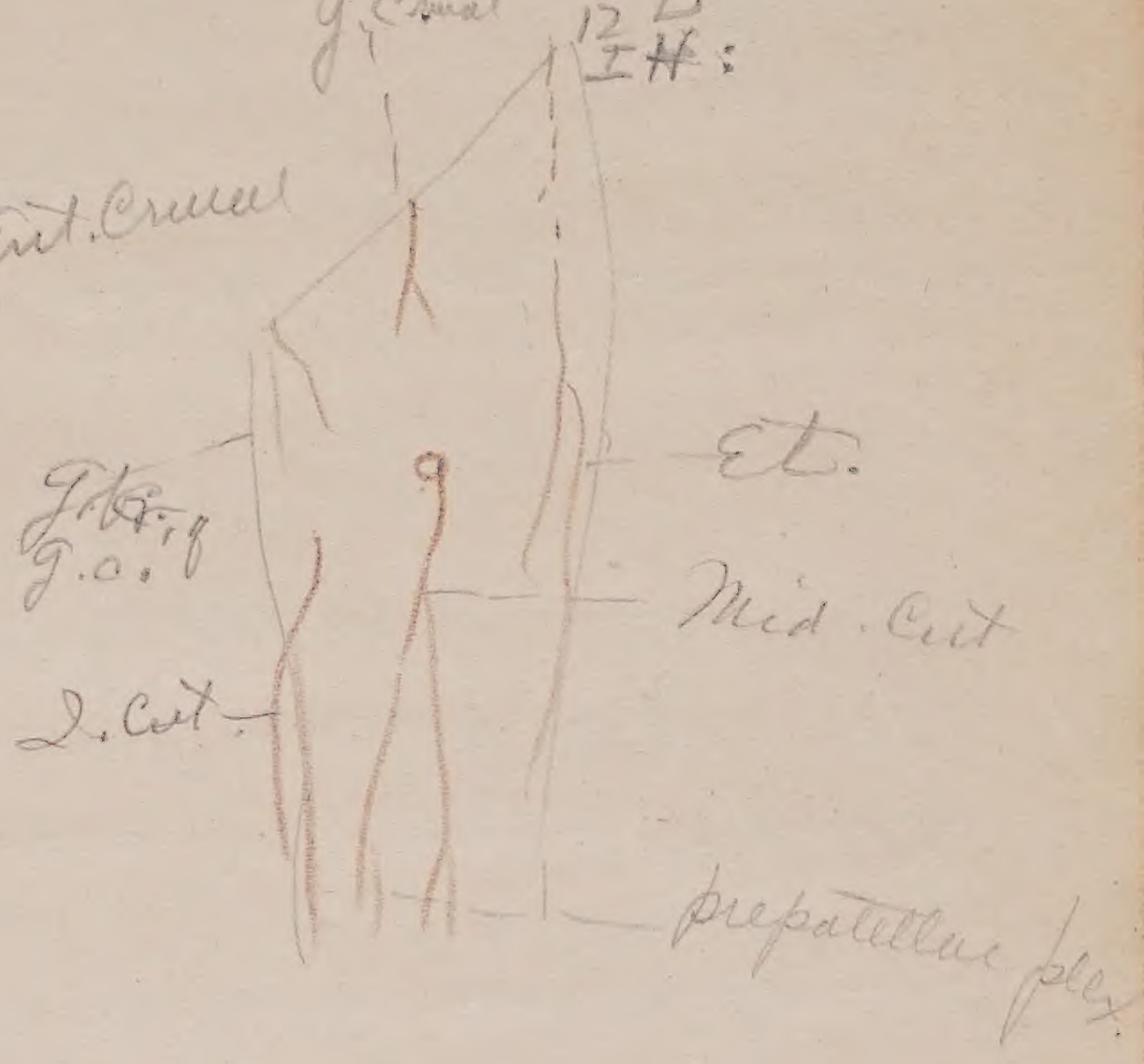

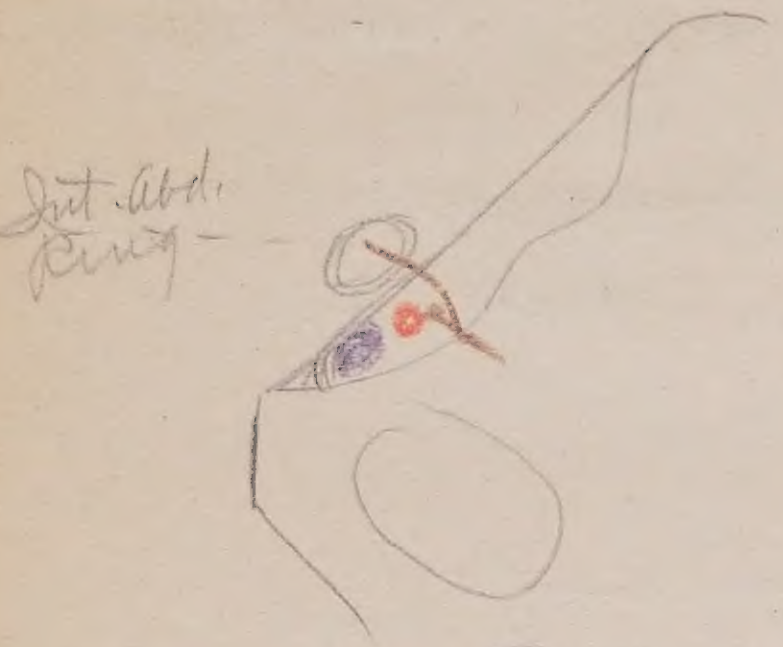

~~Anterior~~ External Cutaneous ^[to Ant. Sup. Spine then under Poup. Lig] supplies skin on anterior aspect of ~~thigh~~ as low as the knee.

Anterior Crural — Emerges in pelvis between Psoas & Iliacus passes through ^[under P.L.] External to Femoral artery

Divides into branches { Muscular, Cutaneous, Articular } In Scarpa's △ just Ext. to artery

Musc. Br. { Supplies Sartorius Iliacus & Psoas, Pectineus, Quadriceps Extensor,

Anterior Crural

Cutaneous Branches { Middle Cutaneous
Internal Cutaneous
Long Saphenous

Articular Branches { Hip Joint and
Knee-joint

Middle Cutaneous - becomes cutaneous
forms pre-patellar plexus

Internal Cutaneous

Long Saphenous - thru Scarpa's △
Hunters Canal, behind intern condyle
becomes cutaneous on inner aspect
of leg, runs along inner side of
big toe. Not a nerve to thigh, but
to big toe.

Branches to Knee - are continuation
of nervesfrom Vasti Muscles.

Sat. 9-10.

Obturator Nerve — from 2, 3, 4th Lumbar
Course along side wall of pelvis



One branch goes above Adductor brevis
and " " below.

Has Muscular and Articular branches.
(Nerve supplies skin over muscles which it supplies, as a rule.)
Supplies Adductor group of muscles (3)
Pectineus, and Gracilis, and Obturator Externus — Through branch to Adductor magnus, supplies knee-joint, and also hip-joint. (Hip-joint disease often is referred to knee by reflexion)

Superficial branch (over Add. brevis) - passes under Sartorius, and helps to form Sub-sartorial plexus.

Sacral Plexus =

Muscular branches - arise in pelvic cavity, supplying muscles in that region -
- Pyriformis
- Coccygeus
- Obturator internus
- Gemelli (Sup. and Inf.
- Quadratus femoris.

Superior Gluteal ~~Muscles~~ Nerves run out of pelvis ~~above~~ the pyriformis, and all others pass below the pyriformis.

Supplies
- Gluteus medius
- Gluteus minimus
- Tensor fasciae femoris

2 branches -
lower branch to hip-joint

Inferior Gluteal - passes below pyriformis - to Gluteus maximus

Great Sciatic - passes below pyriformis to upper limit popliteal space, divides into Internal and External popliteal

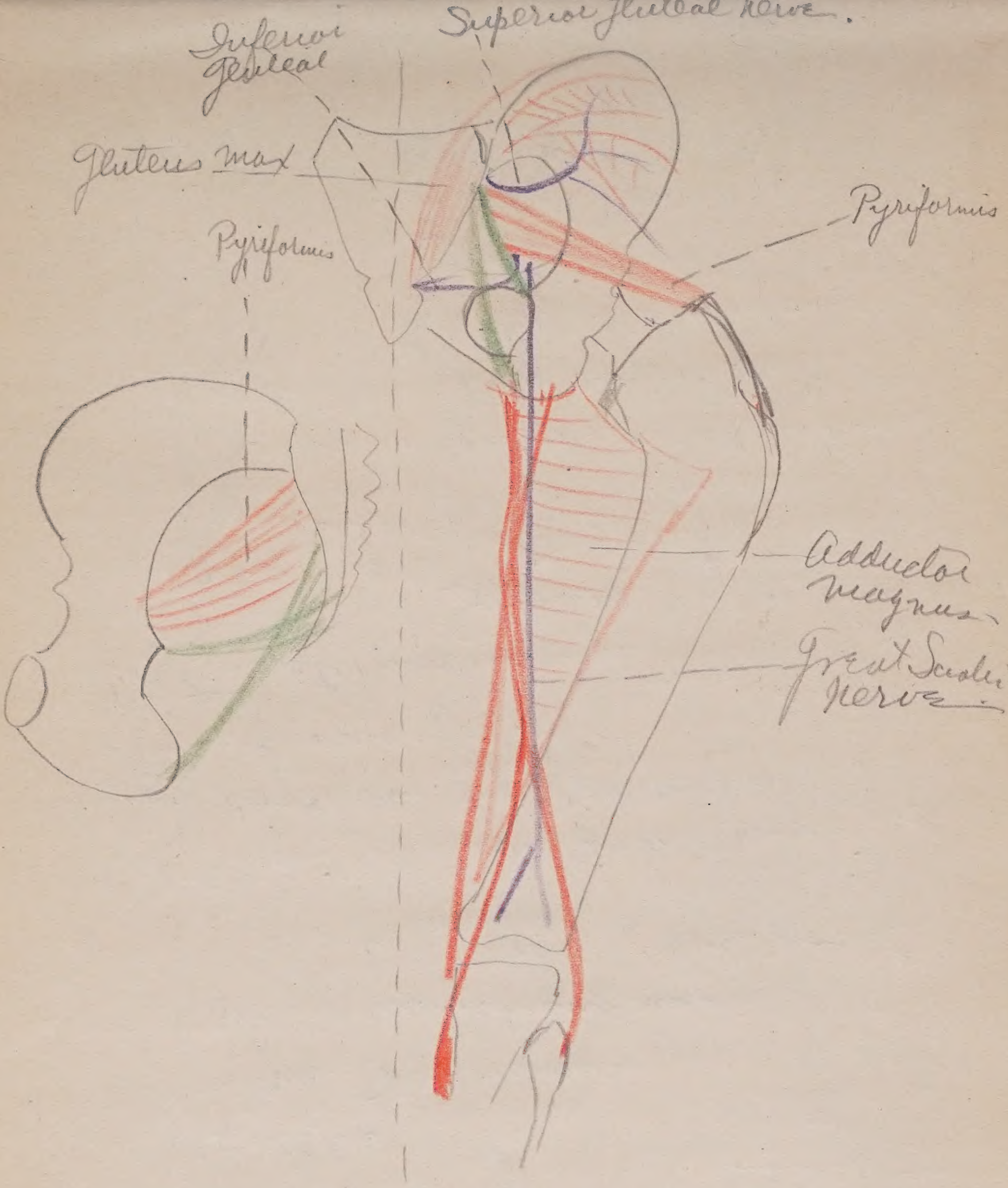
Inferior Gluteal
Superior Gluteal nerve.
Gluteus max
Pyriformis
Pyriformis
Adductor magnus
Great Sciatic nerve

Great Sciatic runs down midway between tuberosity of Isch. and lesser trochanter of femur — passes between 2 planes of muscles — Upon adductor magnus, and between Hamstring muscle. Supplies:

- Adductor magnus
- Biceps
- Semi tendinosus
- Semimembranosus
- Also branches to hip-joint

Just below gluteus maximus, it is not covered by muscles — but by skin, fascia, fat, etc.

Continuations



External Popliteal (Peroneal) passes down under Biceps and winds around neck of fibula to get in front. Very superficial.

The Enters substance of Peronei muscles Peroneus longus — divide into 2 branches

~~External Popliteal~~

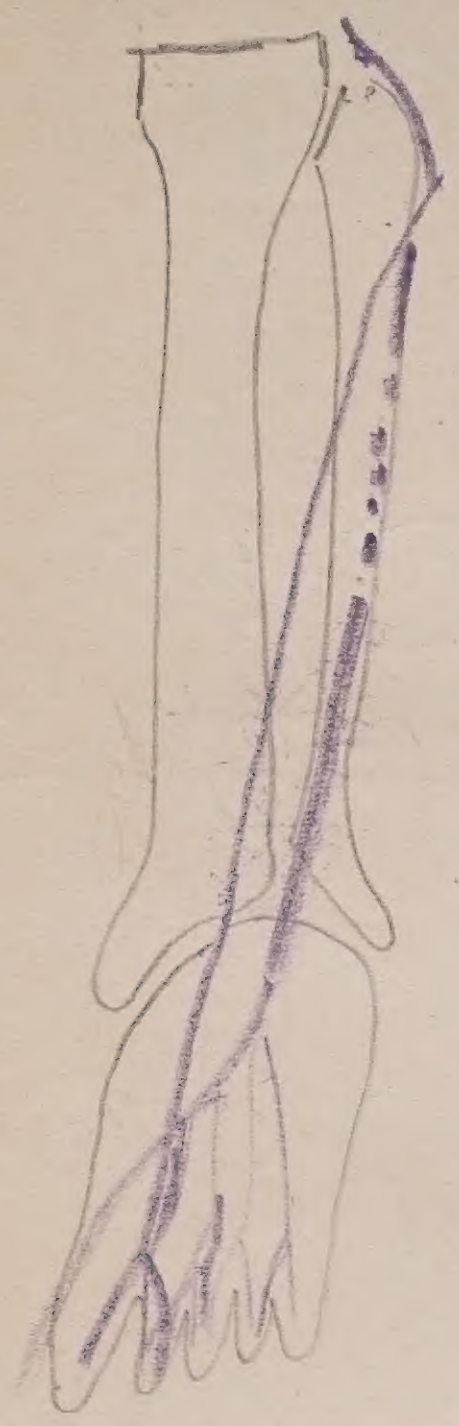

Anterior Tibial branch runs to Interosseous Membrane, ~~with~~ along outer side of Ant. Tibial Artery over bones of foot, to Inner side of big toe, where it divides into two terminal branches to big toe and second toe.

Supplies muscles between which it runs:—

- Tibialis anticus
- Ext. long. digitorum
- Ext. proprius hallucis
- Peroneus tertius
- Ext. brevis digitorum

Musculo-Cutaneous branch — on outer side of leg — supplies

- Peroneus longus and
- Peroneus brevis

In middle part of leg becomes sub-cutaneous — divides into seven digital branches — one branch to inner side of big toe.

Short Saphenous — outer side of little toe

Popliteal artery has 5 articular branch

Branches of Popliteal Nerves correspond to those of Popliteal artery.



Internal Popliteal — at lower edge of Popliteus muscle, it becomes
Posterior tibial — down inner side to Internal Malleolus —
divides into { Internal Plantar
External Plantar

Supplies Superficial plane of muscles
{ Plantaris
Gastrocnemius
Popliteus

Also Sup. Int. Art.
Inf. Int. Art.
Azygos artic.

[illegible]

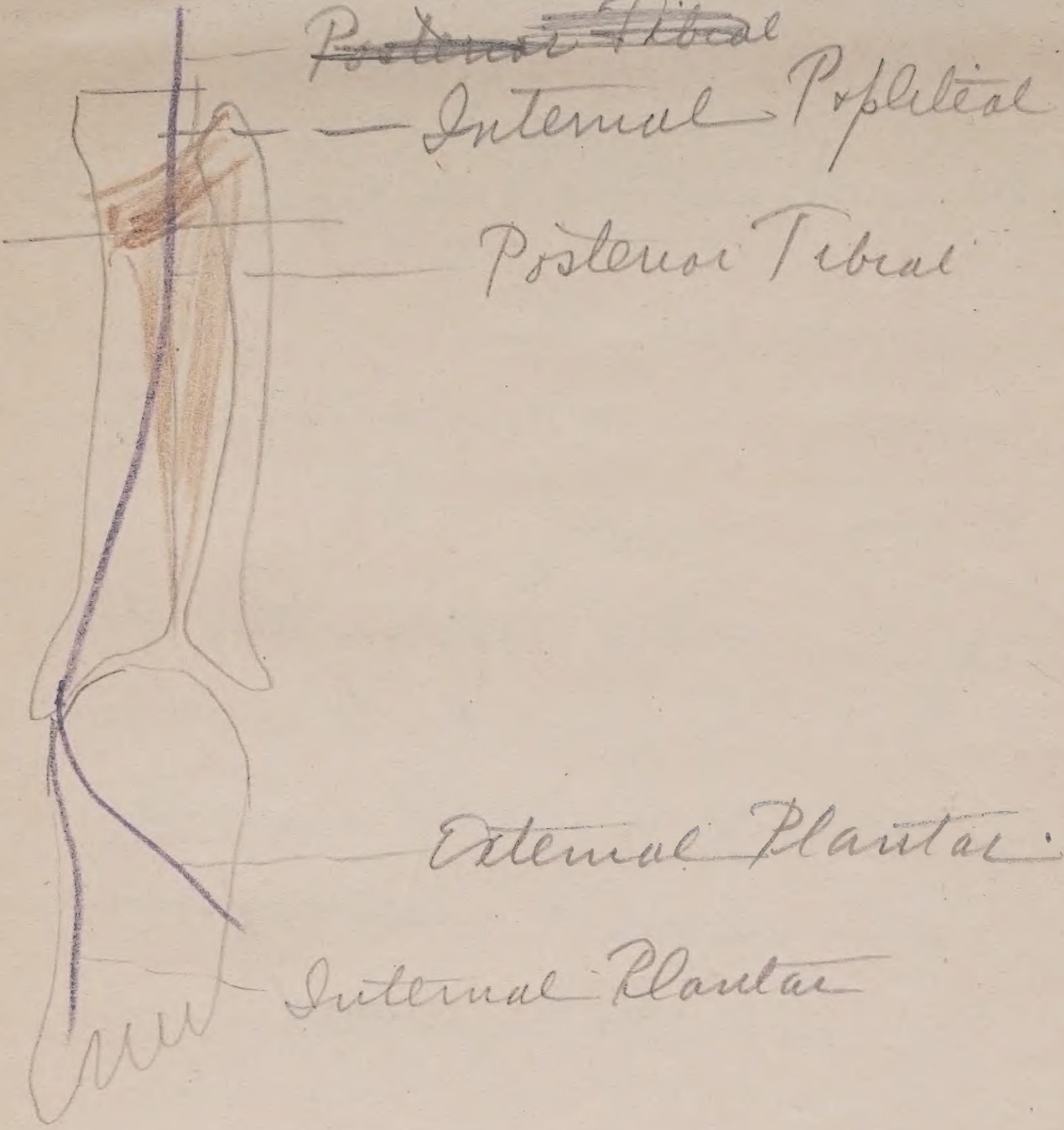

Flexor longus digitorum
Flexor longus hallucis



Tibialis posticus
Flexor longus digitorum
Venae comites
Posterior Tibial nerve
~~Peroneus~~ lo

April 18, 1906

Arteries

Aorta - first portion begins at heart — Left Ventricle at apex of Aortic Vestibule; upper angle of 3rd intercostal space, angle formed by lower border of left 3rd rib with sternum. Runs upward and to right to 2nd intercostal space on right side. Then to right, forming an arch, highest point at upper border of 2nd rib; then downward, becoming thoracic Aorta at 4th Dorsal Vertebra on left side.



Ascending Portion of Aorta is intrapericardial.
Arch is extra pericardial.

Anterior to 1st Portion.
Pulmonary Artery
Rt. Auricular Appendix.
Post. to Left Auricle.
Sup. Vena Cava.
Right Bronchus,
Lungs and
Pleura



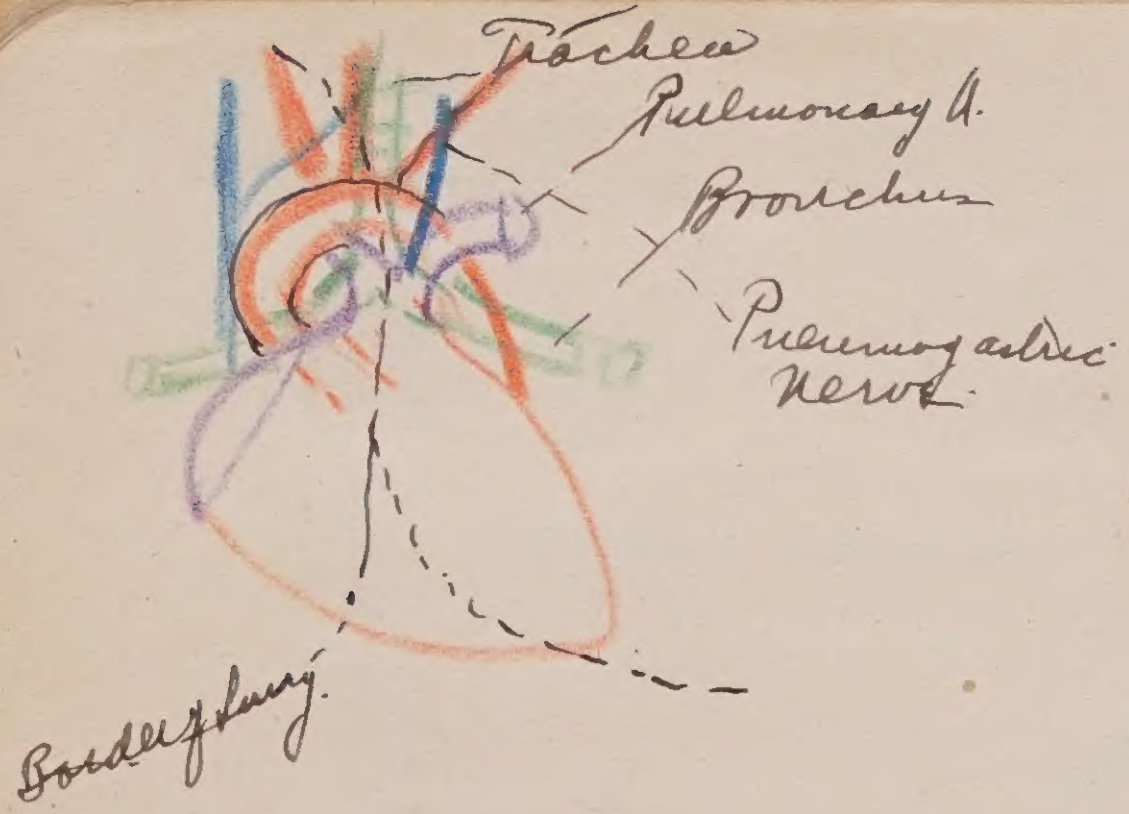

Anterior to Aorta, find Pulmonary Artery and right auricular appendix.
Trachea bifurcates at 4th Dorsal Vert., one bronchus passing to each side.
Left Auricle behind 1st portion of aorta; also superior Vena cava.
Whole of arch ~~of~~ Aorta, is covered by pleurae and lungs.
3 branches from arch of aorta
Innominate
Left Carotid
Left Subclavian.
Thymus Gland in this region.

Thoracic Aorta – from 4th to 11th Dorsal Vertebra. Rests on vertebrae. In upper portion, to right find Oesophagus, arching over aorta to get to left. Begins to cross at about 7th Dorsal vertebra; enters stomach at about 10th Dorsal Vert.
~~Left~~ Azygos Veins – Aorta in front of them



Thoracic Duct – behind lower part of Aorta; in upper part between aorta and Oesophagus.

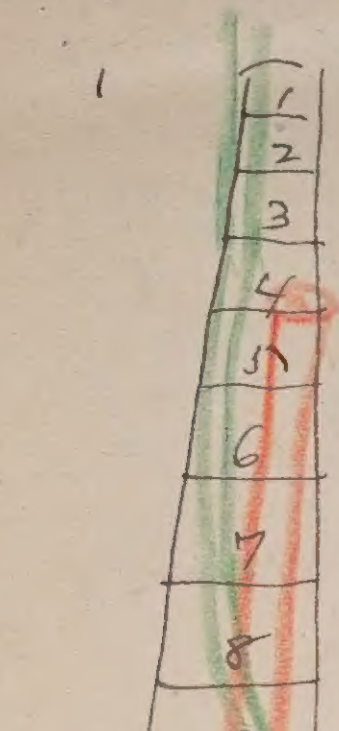

Embraced on left side by pleura above and by right pleura below.
10-11 Azygos Arteries.
Gives off a few pericardial arteries.

Abdominal Aorta —

Begins where it passes under crura of diaphragm in median line, passes somewhat to left, and bifurcates at 4th Lumbar Vertebra into Rt. and Left Common Iliac Arteries.

Inf. Vena Cava to right of it.

Branches — 2 types
Visceral
Parietal.

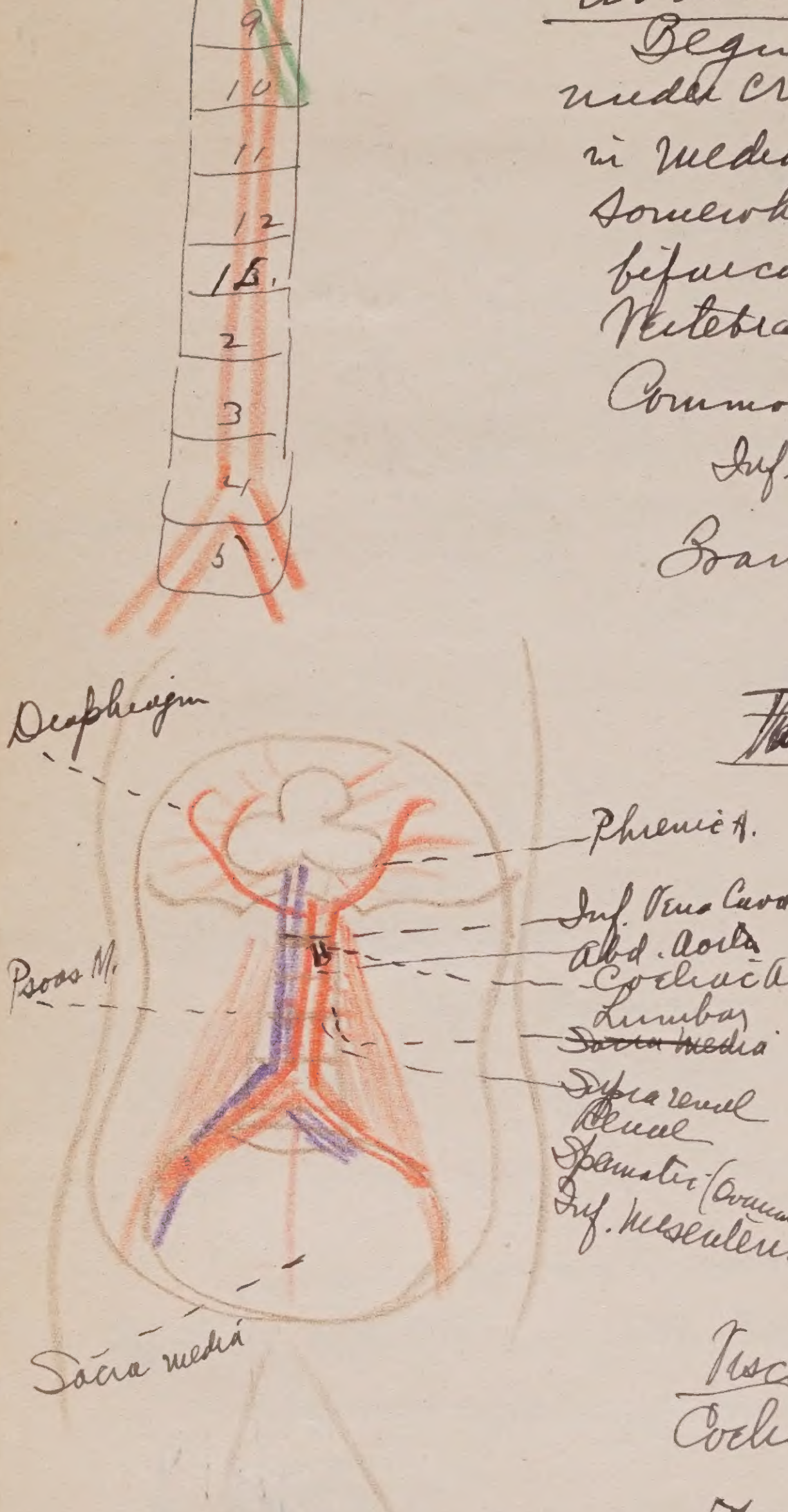

Parietal —

2 Phrenic — supply diaphragm, anastomose with Internal Mammary.

5 Lumbar arteries — supply parietes under Psoas.

Sacra media Art. runs on sacrum down to coccyx.

Visceral branches.

Coeliac Axis — at junction of 1st and 2nd L. Vert.

Coeliac Axis –
gastric
~~Hepatic~~
~~Splenic~~ -
~~Superior Mesenteric~~.

Renal Arteries – At about 2nd Lumbar vertebra.
at lower border of pancreas

Supra-renal Arteries – just above renal art
Spermatic or Ovarian – below renal; sometimes come from renal.
Inferior Mesenteric

April 23/06.

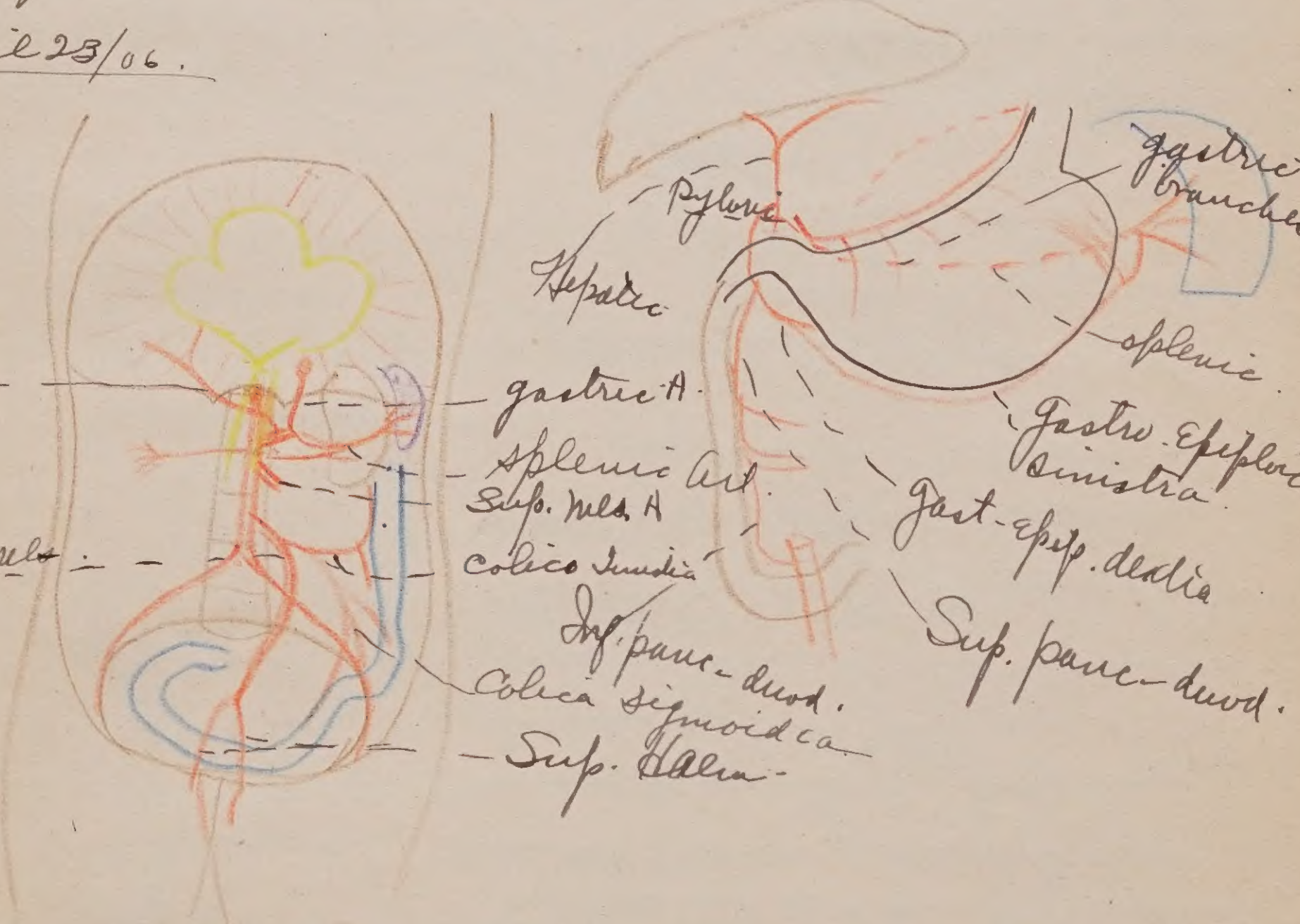

Coeliac Axis
Gastric
Hepatic
Splenic.

Gastric Artery – coronary branch.
1. the post. wall to oesophagus – anastomoses
with pyloric branch of hepatic.

Pancreatic branches.

Splenic = Passes over kidney, over pancreas through Lieno-renal ligament into spleen.

Pancreatic branches - great blood supply of pancreas.

Gastro-epiploica sinistra - to stomach

Hepatic - runs up in Gastro-hepatic Omentum - 2 terminal branches (right lobe & left lobe). - branches -

Pyloric - anast. with Gastric artery.

Gastro-duodenal branch -

Gastro-epiploica dextra

Sup. Pancreatico duodenalis (anast. with Inf. panc-duod. from Inf. mesenteric

Cystic artery -

Right branch gives off a branch along cystic duct - which div. into 2 terminal branches. 1 to gall bladder

1 to ~~peri~~ subst. between gall bladder and liver substance

Superior Mesenteric Artery - at about 2nd Lumbar Vert. curvature convexity towards the right.

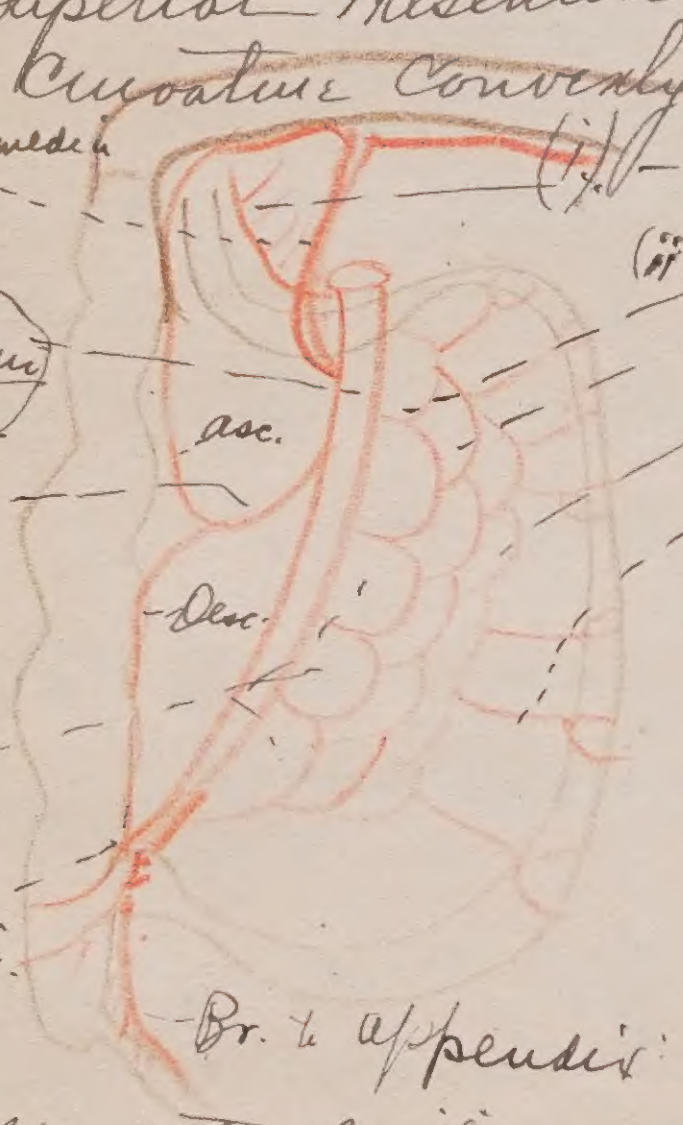

(i) - Inf. pancreatico-duodenalis

(ii) Primary arches

- Secondary arche

- Tertiary arches

- Arteria recti

In beginning of jejunum, there are no loops, in middle, 2-3-or 4 loops.

Vasa intestini tenuis.

In mesentery, many lymphatics and much fat, particularly in lower portion

On upper portion semilunes are transparent in lower fold. opaque

These small arteries are "said" to anastomose along mesentery, but this is very insignificant. (Ard between arteria recti).

(iii) Colica media - a branch of Sup. Mes. Running up in mesentery of transverse colon.

(iv). Colica dextra - anast.

2 branches Ascending

Ascending - anast. with Ilio-colic

At Ilio-colic portion divides into 2 br.
Anterior & to small intestine
Posterior
Artery of Appendix.

Inferior Mesenteric - comes off Abdom. Aorta about $1\frac{1}{2}$ in. above its bifurcation. Crosses into pelvis. at about 2nd piece of sacrum becomes Superior Haemorrhoidal - 2 branches along sides of rectum, piercing lower half of rectum & get into mucosa; terminates at anal canal, anast. with Inf. Haemorrhoidal.

Renal artery - Comes off at lower border of pancreas. Several branches enter hilus of Kidney.

Inferior Supra-renal artery - comes from below Sup. renal capsule. This also has its own Supra-renal artery from above.

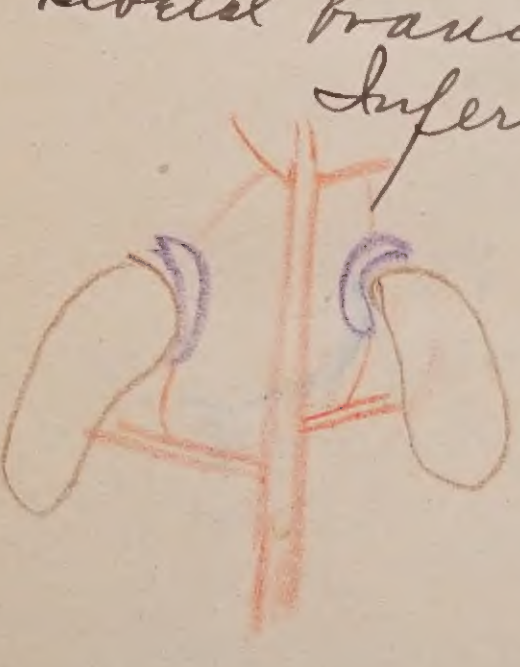

April 25/06.

Spermatic (or Ovarian, in ♀)
Usually come off from aorta; - may be

connected with Renal

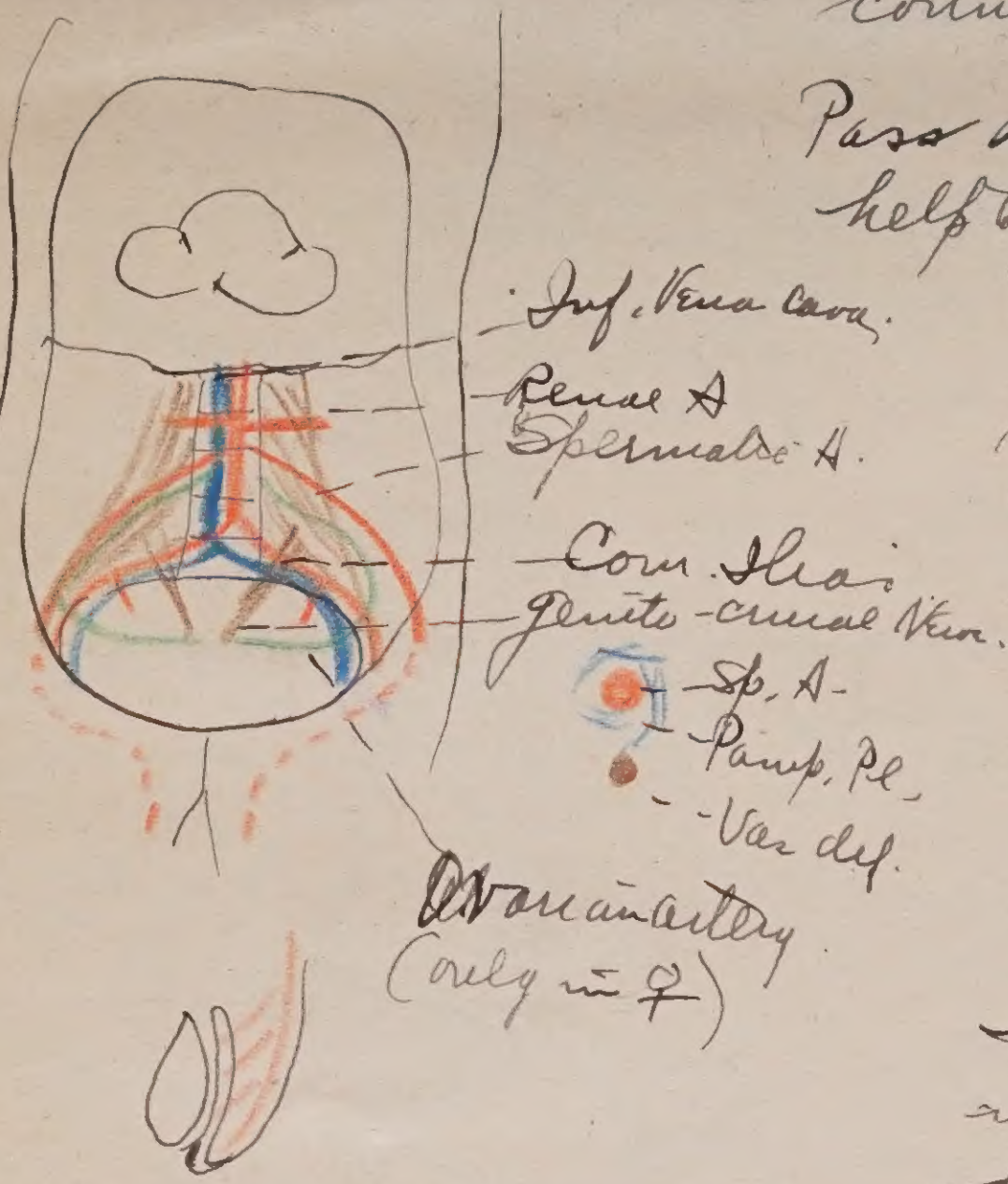

Pass down to internal ring; help to form sperm. cord. Placed with Pampiniform plexus in front of vas deferens. Branches to Epididymis. Spermatic Cord also contains artery of vas. (Import. in varicocele).

In female. Ovarian artery in same way; passes down side of pelvis, turns inward, passes over free edge of Broad Ligament, to anastomose with uterine artery

Sacra media - termination of aorta - passes down to tip of Coccyx - in Body of Luschka.

Common Iliacs - Begin at 4th Lumb. Vert, about ½ in. to left of median line; (opposite promontory of sacrum divide into Int. and Ext. Iliac.

Ext. Iliac - Extends around brim of pelvis to outer edge of Psoas muscle, passes under Poupart's lig at midpoint between Ant. Sp. of Ilium and Spine of pubis, where it becomes Common Femoral.

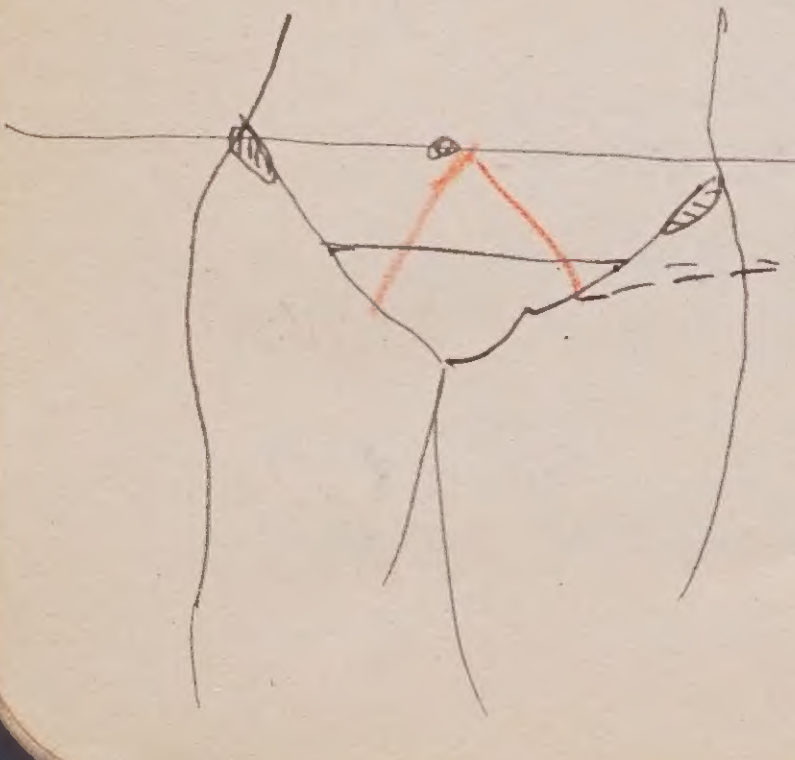

Intertubercular line { Cuts umbilicus / Opp. 4th Lumb. Vert.

— Mid. point. betw. Ant. Sup. Sp. & Sp. pubis

Branches of Com. Iliac. none

Ext. Iliac -
Deep Epigastric
Deep Circumflex Iliac

Inferior Vena Cava on left side. In general, veins in pelvis are on inner side of arteries

Ext. Iliac — branches

<u>Deep Circumflex Iliac</u> — runs up in furrow formed by Poupart's Lig. up to Ant. Sup. spine where it <u>anastomoses</u> with
- Superficial Ext. Iliac
- Superior gluteal
- Iliac br. of Int. Iliac





<u>Deep Epigastric</u> — Comes off com. off ~~Ext.~~ Iliac close to Poup. Lig. — runs up <u>inside Int. abd. Ring</u> — passes beneath Semilunar fold of Douglas to sheath of Rectus abdom. — anastomosing with superior Epigastric (a branch of Internal Mammary) — the <u>longest anastomosis</u> in the body.

Surface marking — mid-Poupart point to Umbilicus.

Important branch (once in 3 times) — gives off the <u>Obturator</u> artery. <u>Important.</u> may go to outer side of <u>femoral opening</u> or to inner side of ring (just skirting Gimbernat's ligament) — this must be

Considered in Every operation for Femoral Hernia

Internal (Direct) Hernia - goes inside of Deep Epig. Art.
External (Oblique) " outside " " "

Internal Iliac Artery -

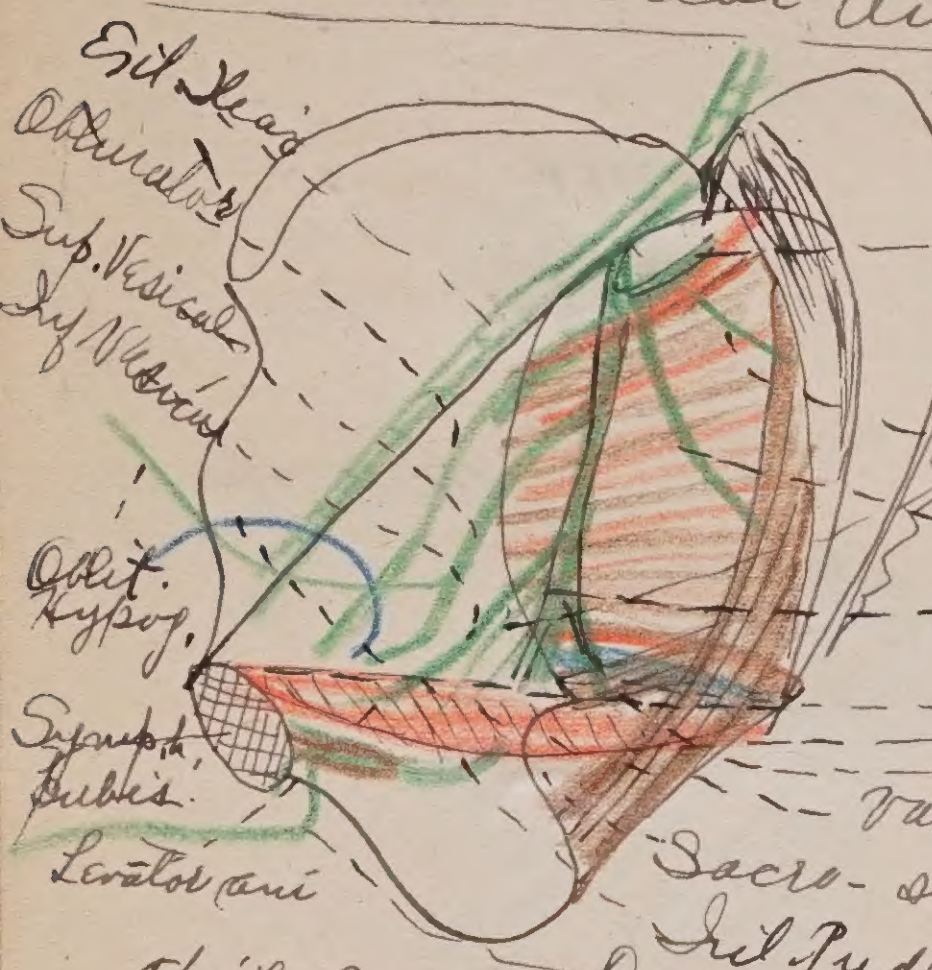

Plane - from symp. pubis, through sp. of ischium to tip of coccyx.

April 30, 1906. -

Internal Iliac - div. opp. pyriformis muscle
into { Anterior { Sciatic
Internal Pudic

Posterior Branch { Superior Gluteal
(Exit from pelvis above Pyriformis)

Ant. Br. Int. Iliac - close to side wall - - branches:
Obturator - passes out at upper limit Obt. foramen.
Superior Vesical - to bladder; br. to abdominal wall = Obliterated Hypogastric.
Often sends off Middle Vesical branch.
Inferior Vesical - also supplies prostate gland
(Ureter internally placed to all these)
Vas deferens also internal.
artery of vas - usually from Sup. Vesical
where Sup. Ves. passes over vas.
Terminal branches -
Internal pudic - winds around sp. of isch., comes in Less. Sci. Notch, passes along

side walls of Ischio-rectal fossa, in fascia: Alcock's Canal, forward to △ ligament.
Terminates in △ ligament in
Dorsal artery of Penis
artery of Corpus cavernosum
Sends branches to rectum
Inferior Haemorrhoidal — insignificant.

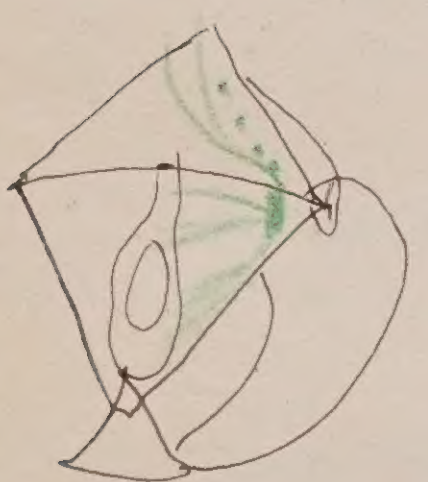

Superficial Perineal artery — runs forward in Colle's fascia {Mesial & Lateral br.

Transversus perinei — small, parallel to Tr. perinei muscle
artery of Bulb — in △ ligament which it pierces to reach bulb. 1/4 to 1/2 in ahead of base of △ ligament.

Sciatic artery — unimportant — Runs down between hamstring muscles and muscle plane below these. Hamstring muscles are supplied by Perforating arteries (4 in number).

Sciatic artery loses itself accompanying gr. Sciatic nerve.

The Crucial Anastomosis — of the Internal and Ext. Circumflex with Sciatic above and Sup. Perforating artery below.

Posterior Branch of Internal Iliac

Lateral Sacral — anast. with Sacra media.

Ilio-lumbar —

Terminal branches — Sup. Gluteal —
By its deep branch supplies
Capsule. Three planes of
muscles supplied — 2 branches
Deep — in medius & minimus
Superficial. — medius & maximus.

May 4/06.

Obturator artery divides into 2 branches in substance of Obturator externus. Obt. ext. supplies hip. joint

Femoral Artery — Begins where Ext. Iliac passes under Poup. lig. — Midway betw. Ant. S. sp. and ~~spine~~ pubis. At junc. of upper $\frac{2}{3}$ with lower $\frac{1}{3}$ turns around to become Popliteal Ar.

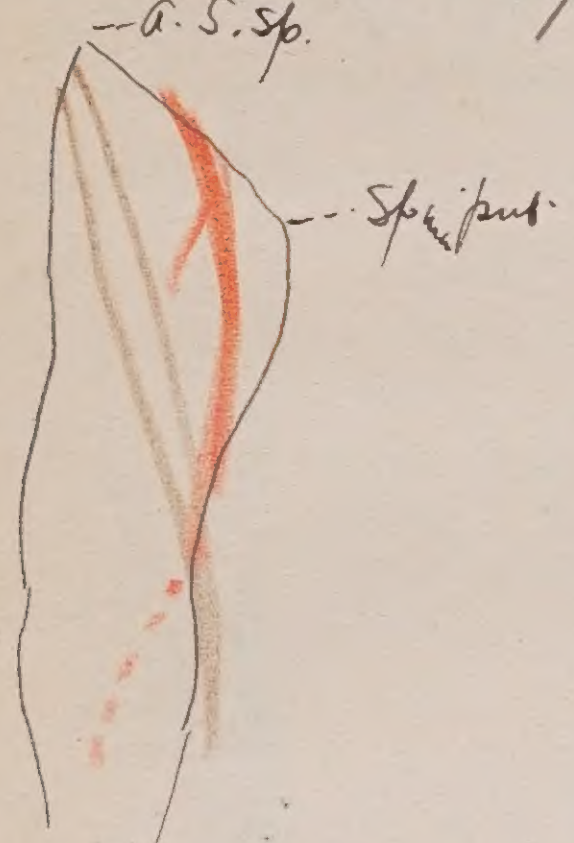

Linear Guide — upper — {midpoint betw. A.S. Sp. & Spine pubis}
Lower — Adductor tubercle

Muscle Guide — Sartorius
In upper $\frac{1}{3}$ inner Edge Sart. m.
In middle $\frac{1}{3}$ outer " "

Com. Fem. Art. $1\frac{1}{2}$ — 2 in. length; divides into Superf. Femoral and Profunda femoris Art.
Superf. Fem. pierces tendon of Adductor magnus to enter popliteal Space
Profunda femoris — passes down a little external behind Add. longus. Rests on Add. magnus. Pierces add. magnus in Popliteal Space as 4th Perforating artery; anastomosing with Popliteal Artery.

These arteries are in two important surgical space Scarpa's triangle and Hunter's Canal.

Scarpa's Δ - Upper and ant. $\frac{1}{3}$ of thigh
Hunter's Canal - Middle and Inner $\frac{1}{3}$ of thigh
Popliteal Space - Posterior and Lower $\frac{1}{3}$ of thigh.

Scarpa's Δ. Base - Poupart's ligament; inner boundary - inner border of add. longus; outer boundary - inner edge of Sartorius muscle. Floor - add. longus, add. brevis, pectineus, Psoas, Iliacus. Roof - Fascia lata, superf. fasc; integuments. (also Saphenous opening).

Hunter's Canal. - Begins apex of Scarpa's Triangle, Covered by fascia to where it passes thru tendon of add. magnus.

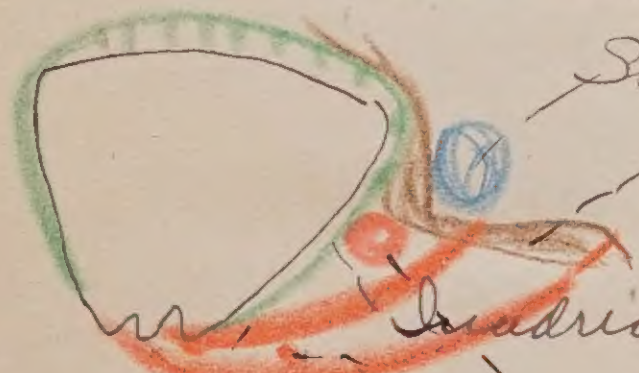

Boundaries - Exter. Quadriceps Ext; Intern. Add. longus and magnus. Roof - fascia, with Sartor. above.

Branches Com. Fem.

~~Superficial~~ External - Branches:-

External Pudic { Superficial External Pudic (in sup. fascia)
Deep External Pudic (across Pectineus muscle)



External Circumflex Iliac - pierces Saphenous opening, runs up to Ant. Sup. Spine

Superficial Epigastric -

External and Internal Circumflex Art. - pass around femur near neck.

Int. C. -- between Iliopsoas and pectineus.

Ext. Cir:- betw. Sart. and Rect. fem. to wind around on capsule

Anastomose posteriorly, forming Crucial Anastomosis.

3 Perforating Branches - perforate Add. magnus. - to reach Hamstring Muscles, which they supply. Not important.

Muscular Branches

Anastomotica br. Superf. Femoral - just as it becomes Popliteal artery.



In pelvis, Inf. V. cava is internal to artery. In Scarpa's △, is internal to artery. Nerve is external to it.

In Hunter's Canal, nerve divides into branches - Long Saphenous crosses over to inner side of artery, supplying skin of leg. Vein continues internal to artery as popliteal vein.



May 7/06.

Anastomotica magna is important in cases of amputation.

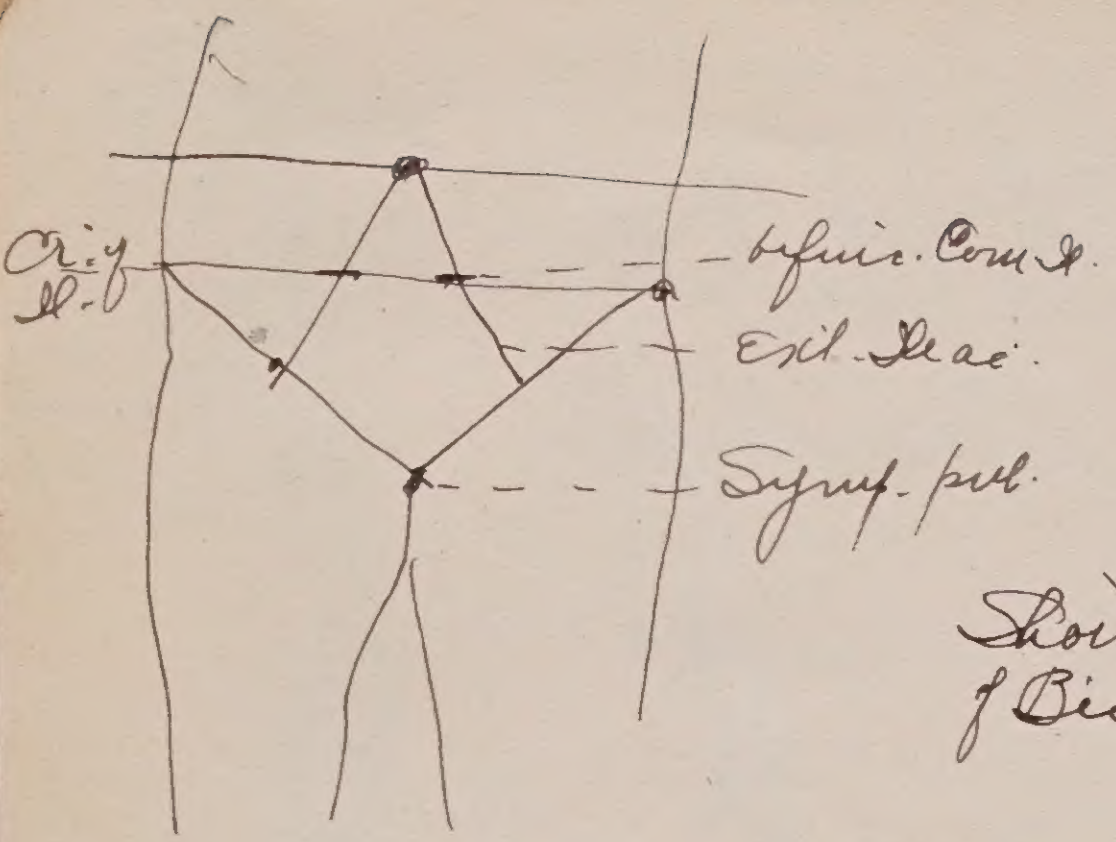

Begin at point just below mid point between Ant. Sup. Spine and Symph. pubis. Ant along outer edge of Sartorius

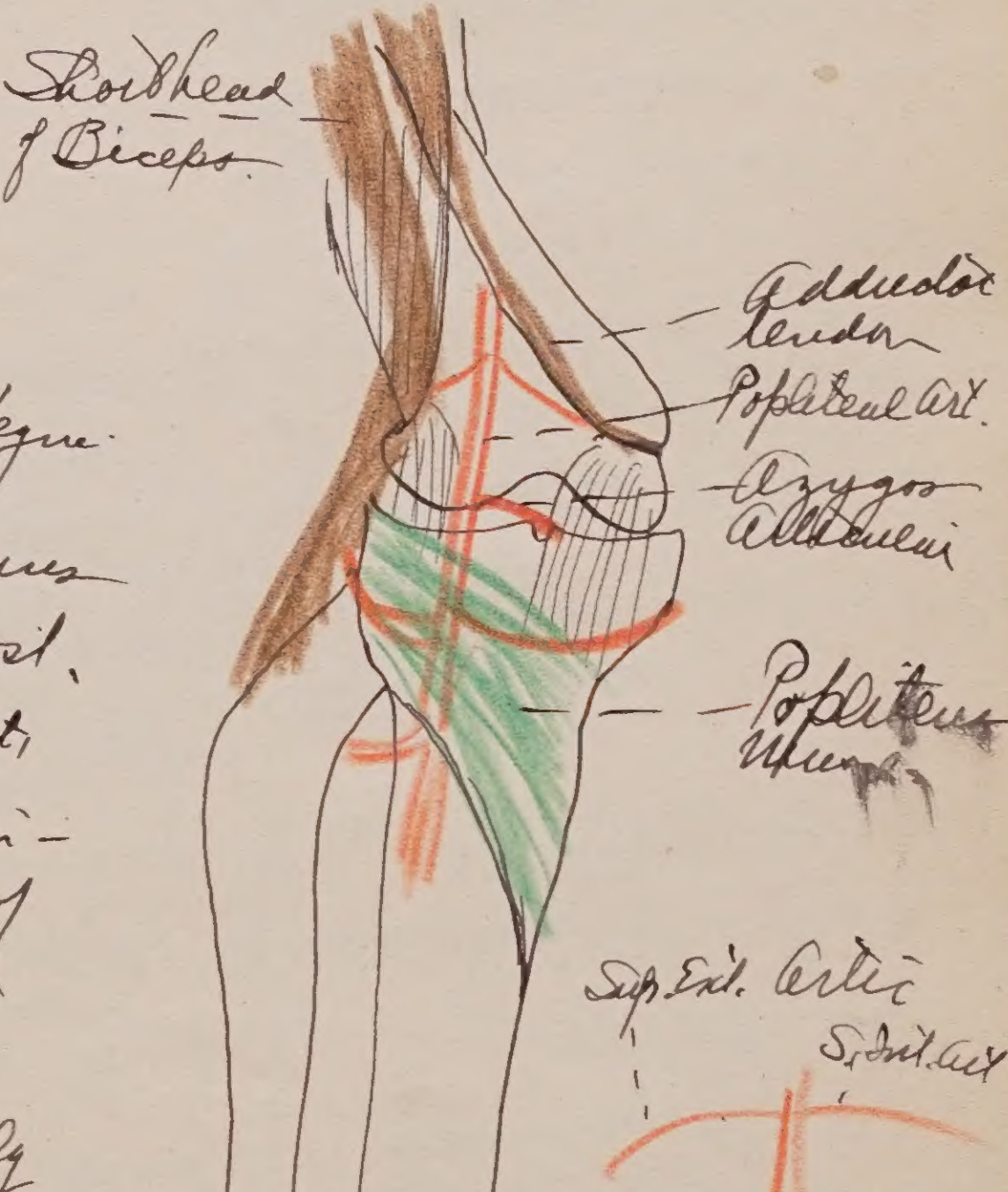

Popliteal Artery — begins at opening in tendon of Adductor magnus, runs down on top of bone, post. ligament of knee joint, popliteus muscle, terminating at lower border of Popliteus Muscle, in Anterior Tibial and Posterior Tibial. Deeply placed.

Branches: —

Muscular Branches
Articular "
Superior Ext. Articular
Sup. Int. "
Azygos "
Inferior Ext. "
" Int. "



Azygos Artic. Art. enters intercondyloid notch, & supply spaces between femur and tibia.

Relations: — Popliteal vein, intimately related, in same fascial sheath. Superficial and externally placed.

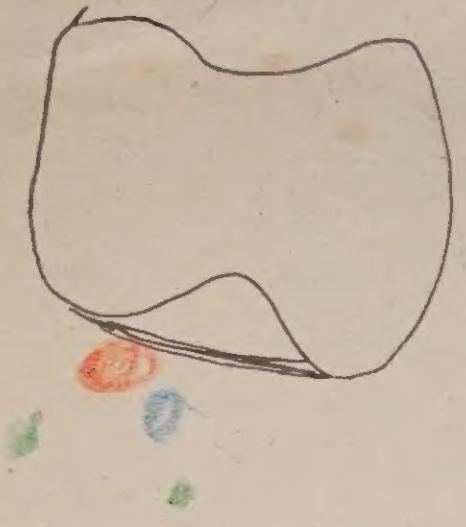

Nerves – Great Sciatic comes down middle; divides into Ext. and Int. Popliteal. Int. Popliteal N. in Ct. to Art. & Vein. Under cover of Biceps

Popliteal Space – Posterior, lower ⅓ of thigh, lozenge-shaped. Boundaries – Above, Externally Biceps; above, internally, Semi-membranosus, Semi-tendinosus; Below, two heads of gastrocnemius.



Floor is Popliteus
Linear guide to Artery is line from apex to base.

May 9/06.

Anterior Tibial –

rests on interosseous membr. runs down to base of metatarsal of great toe; where it passes into sole of foot, meeting there the Ext. Plantar artery, forming arch of foot.
Named Ant. Tibial down as far as malleoli; remainder is Dorsalis pedis.
Linear Guide – take point^depression^ between head of fibula and tubercle of tibia – line^down^ to bifurcation between big toe and 2nd toe. Deeply placed, rests on ligaments and bone.
Dorsalis pedis – is continuation of the Anterior Tibial.

Rather take point between the 2 malleoli

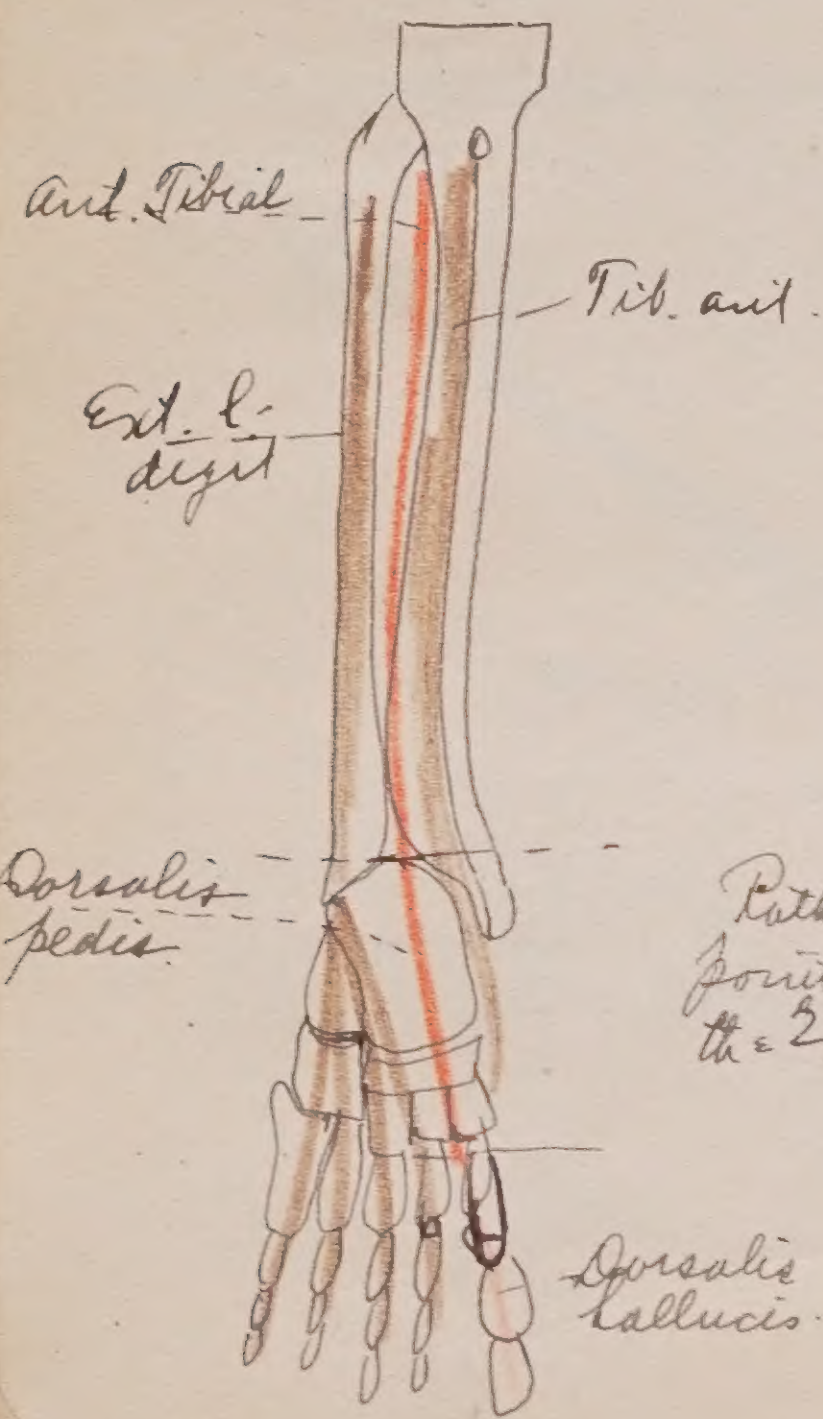

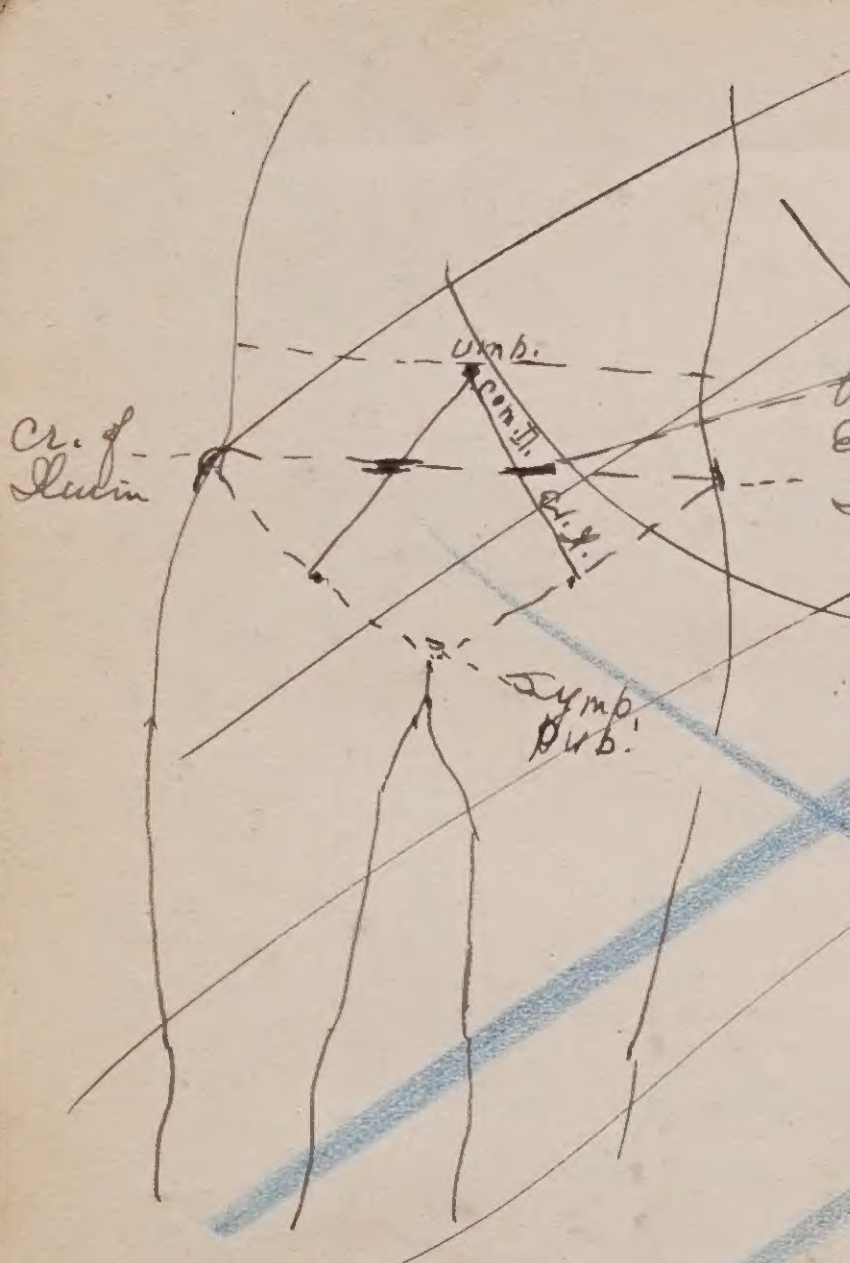

Begin at point just below mid point betw. Ant. Sup. Spine and Symphysis pubis, cut along outer edge of Sartorius

Popliteal artery –



Anterior Tibial artery always to inner side of Tibialis anticus. Extensor longus digitorum is external to it.
Extensor proprius hallucis – from middle half of fibula –

In upper $\frac{1}{3}$ of leg – E. l. dig. ext. Tib. ant. int

In middle $\frac{1}{3}$ – E. l. hall, ext. Tib. ant. internal

In lower $\frac{1}{3}$ – E. l. dig. ext. and Ext. l. hall. internal

Extensor brevis digitorum – sends a tendon to long tendon of big toe, reinforcing it

Branches (not important)

Posterior Anterior Tibial Recurrent
Anterior Tibial Recurrent – to knee joint
Fibular branch
Muscular Branches

Internal Malleolar
External Malleolar
Tarsal Branches
Metatarsal Artery
Dorsalis hallucis
Digital branches

In lower portion, Ant. Tibial frequently make a great curve laterally

Posterior Tibial – begins at bifurcation;

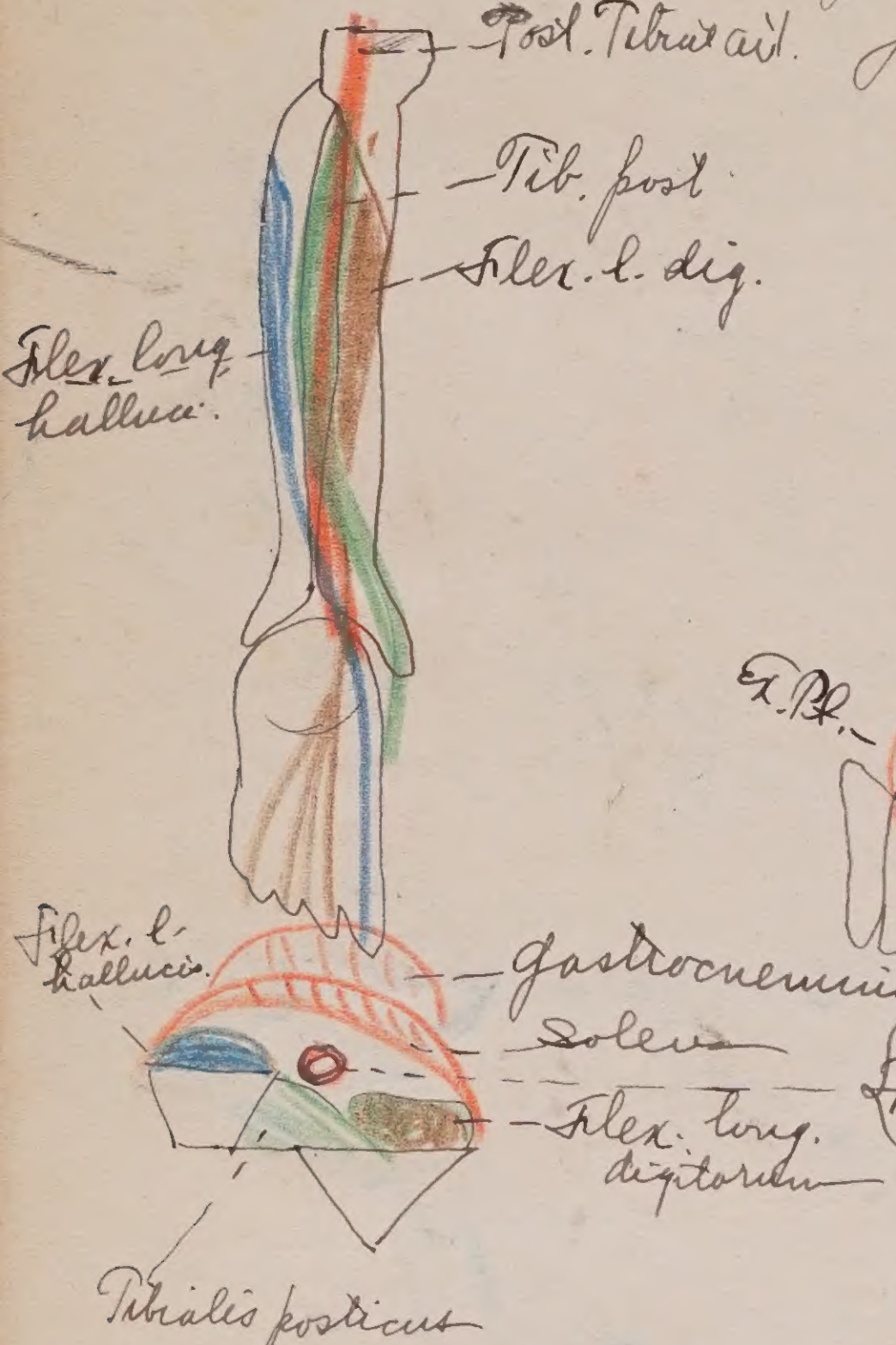

Goes down between 2 planes of muscle (Tib. posticus,

at Int. Mall – Tib. post. (int), Flex. l. dig. (next) –; Flexor l. hallucis (Ext.)
On top of it. Soleus m.
at Malleolus, divides into Ext. and Int. Plantar.
Int. Plantar term. in cutaneous br. around big toe

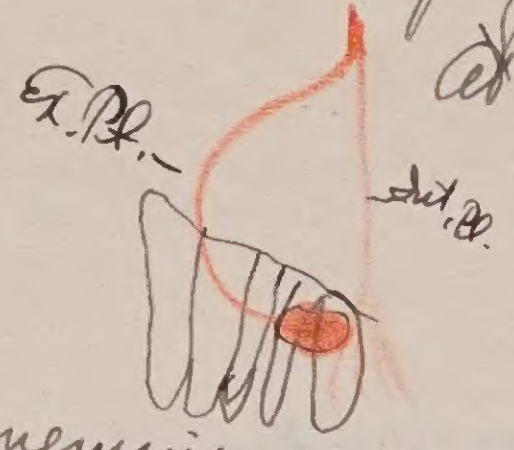

Ext. Plantar. meets Dorsalis Pedis.



Radial artery winds around wrist to point between base of thumb and 1st finger, where it perforates to front.

Supplies Dorsal arteries of thumb and forefinger and digital branches



Ant. Tibial artery has course much the same.

May 14/06 Posterior Tibial Artery

Linear Guide – Take midpoint of popliteal space, and draw line down to midpoint between Int. Malleolus and tip of os calcis

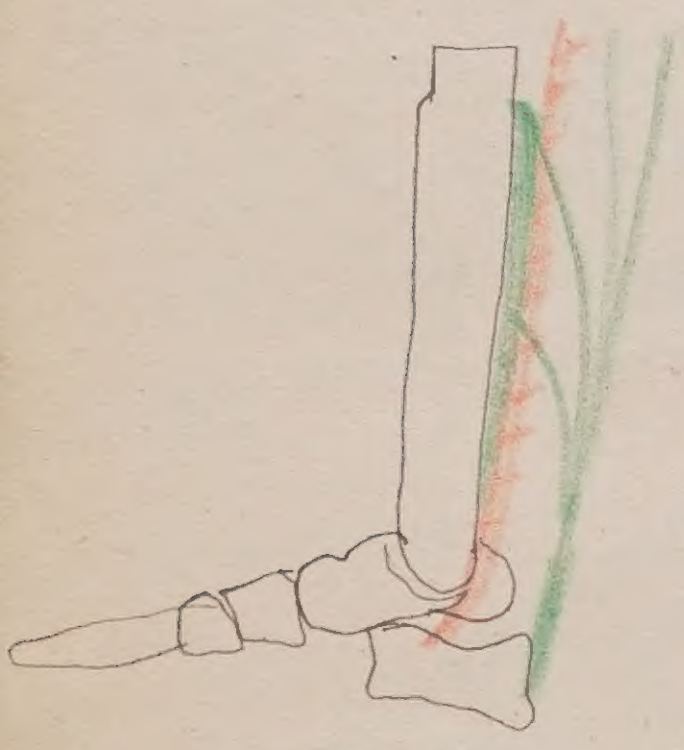

Easier to attack artery from the side:– Linear Guide – Take thumb's width behind tibia above and fingers breadth below. Above – must cut through Soleus M., below, artery lies upon tendons of muscles.



Solens Muscle always ~~covered~~ lined by a layer of dense yellow fascia

Dissection of Post. Tib. Artery – Push Int. Popliteal nerve aside externally; Int. Popliteal Vein in close rel. to Artery;



Timothy – Tibialis posticus
Doth – Flex. l. digitorum
Vex – Vena comitas
All – Artery (Post. Tib.
Very – Vein
Nervous – Nerve (Post. Tibial
People – Flex. l. pollicis

At Int. Malleolus divides into Ext. and Int. Plantar

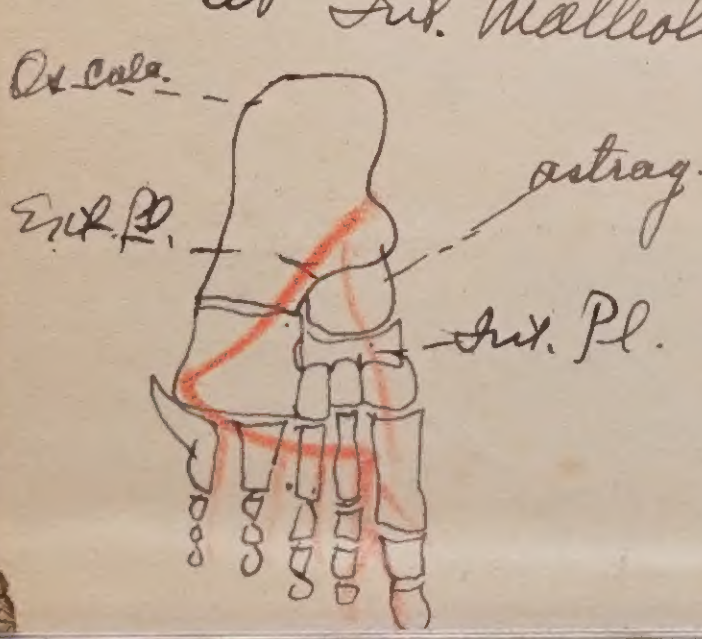

Ext. Plantar runs over to base of metat. of little toe; then across bases of met. of all toes, to point between big toe and next toe, meeting dorsalis pedis. Gives off interosseous branches

Internal Plantar – runs lower be Fl. br. ~~poll.~~ min. dig. and Abductor pollic;
terminates at ball of big toe.
At ankle – relations: – front malleolus backwards,
On sole of foot – beneath Super. muscles, Flex brevis p., Ab. min digit; flex. brev. digitorum

Ex. Branches –

Posterior tibial gives off almost immediately
Peroneal Artery – runs over fibula, running down in substance of Flexor l. hallucis muscle – in lower portion sends one branch in front and one behind

May 16/06.

Upper Extremity –

Aorta –
Right and Left Coronary 1st branches of the road blood supply of heart.





3 great branch.
Innominate Art.
comes off med plane
Right Subclavian

Left Subclavian

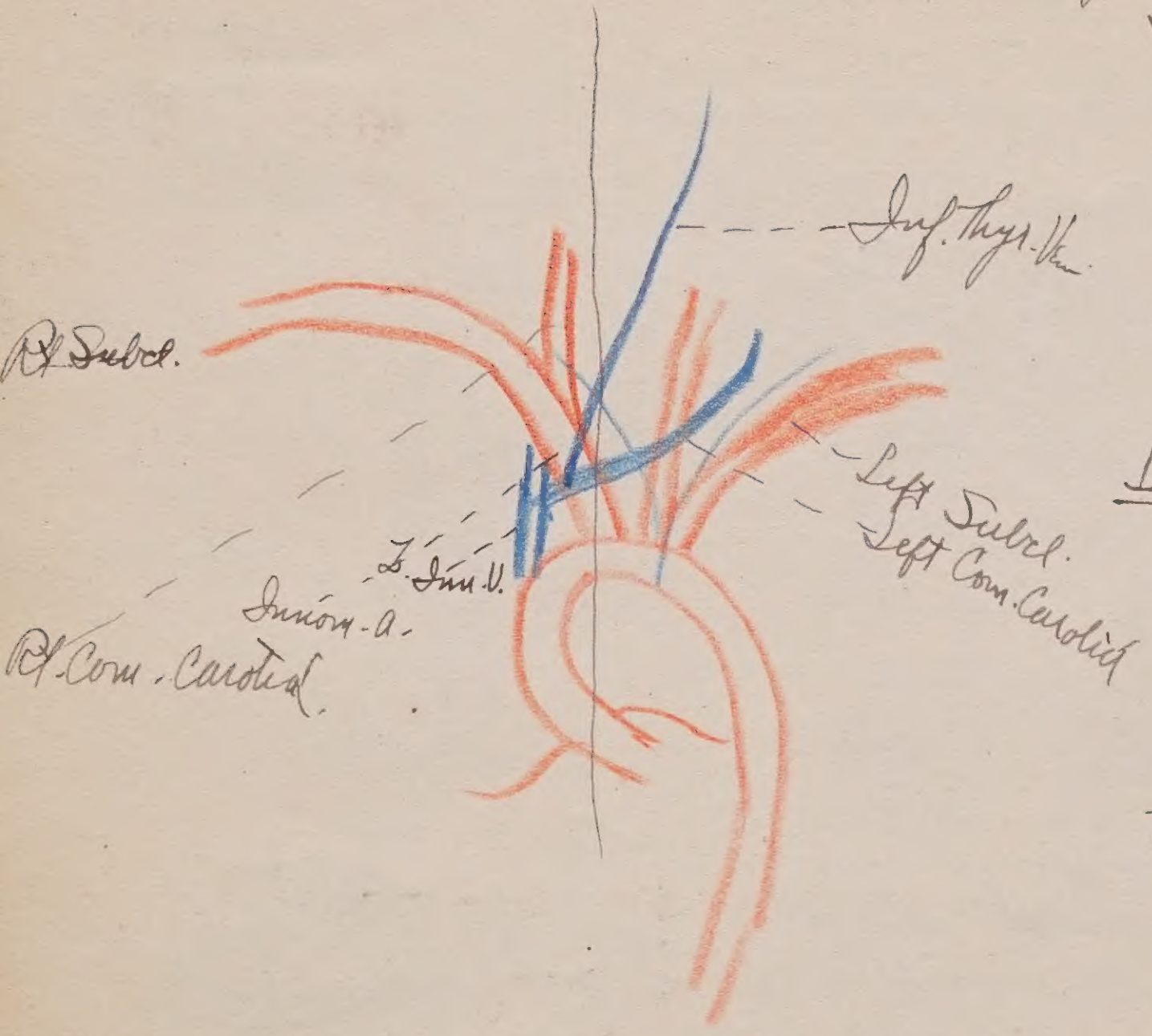

Innominate bifurc. at Sterno-clavic. artic. into Rt. Subcl. and Rt. Com. Carotid.
Left Carotid a. begins at arch - runs upw. to left -

(hardly the pleura);
anterior to Innominate artery - 1st piece of Sternum, depressors of Hyoid bone; remains of Thymus gland; Left Innominate and Inf. Thyroid veins.
Posteriorly - rests on trachea (anterior aspect) brachio-cephalic vein; pneumogastric N., etc.
Left Common Carotid - covered anteriorly by lung and pleura. Begins at St-clav. artic. runs up on transv. processes of cervical vertebrae to upper limit of thyroid cartilage; branches into Int. and Ext. Carotid; Internal Carotid is real continuation continue along transv. proc. of vertebrae to enter petrous portion of skull (deeply placed) -
Common Carotid, as it passes upward gradually diverges from its fellow of opposite side.
External Carotid approaches the Median plane.

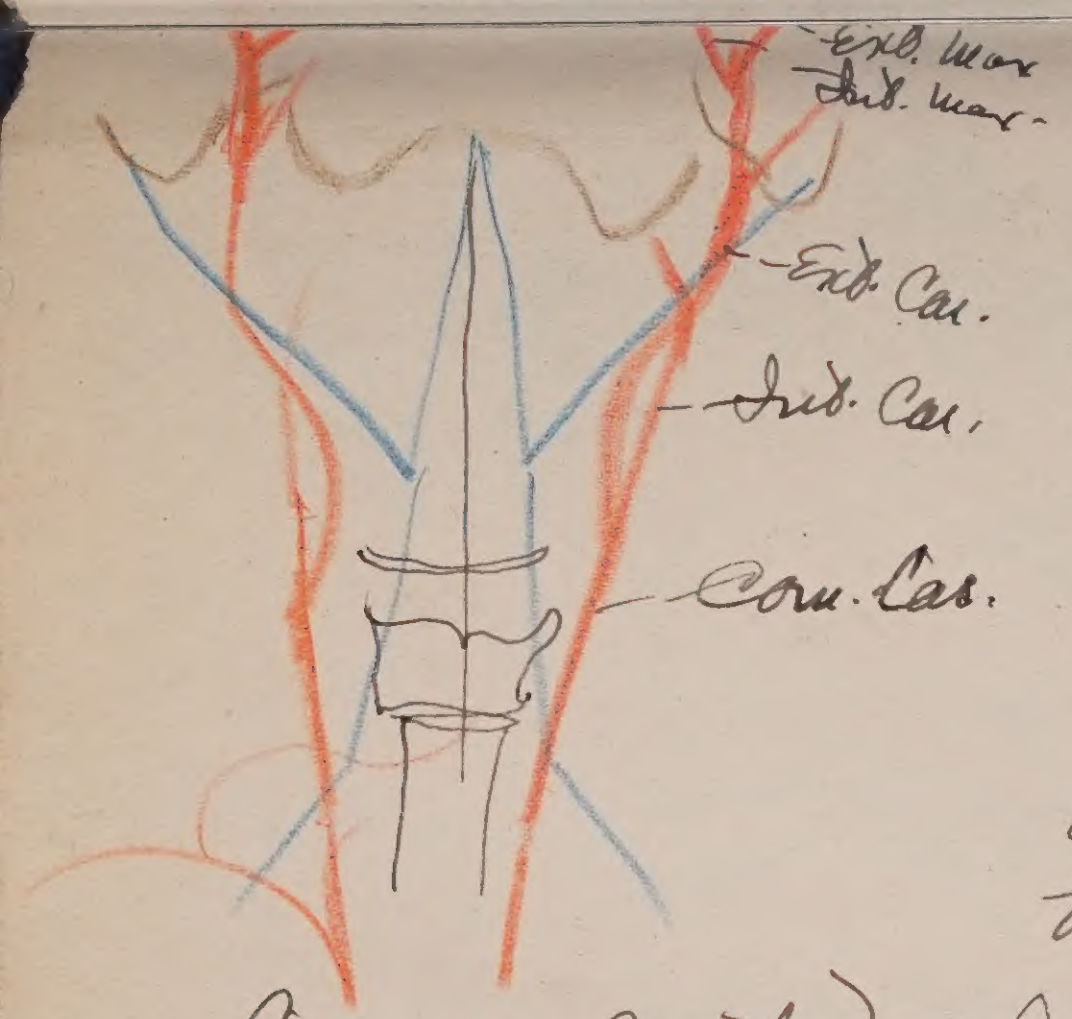

then curves outward to a point midway between angle of jaw and mastoid process, enters substance of Parotid gland, and at condyle of jaw bifurcates into Int. and Ext. Maxillary.

External Carotid is the visceral artery of the neck

Common Carotid } External Carotid } — Lineal guide — line from sterno-clavicular articulation to a point midway between angle of jaw and the mastoid process

Muscular guide — inner border of Sterno-Cleido-mastoid M.

Relations — Com. Car. A. rests in Inf. Car. △, where it bifurc. and Ext. Car. Art. rests in Digastric △ and Sup. Car. △. (Muscle Triangle — Triangle of Necessity)

In Inf. Car. △ posteriorly — on transv. proc. of Cerv. Vert (Longus colli, Scal. anticus). Near level of Cricoid Cart., Inf. thyroid art. passes behind Com. Car. Sympathetic Chain Ganglia of neck, behind the vascular sheath; between Art. and Vein in sheath, is pneumogastric N.

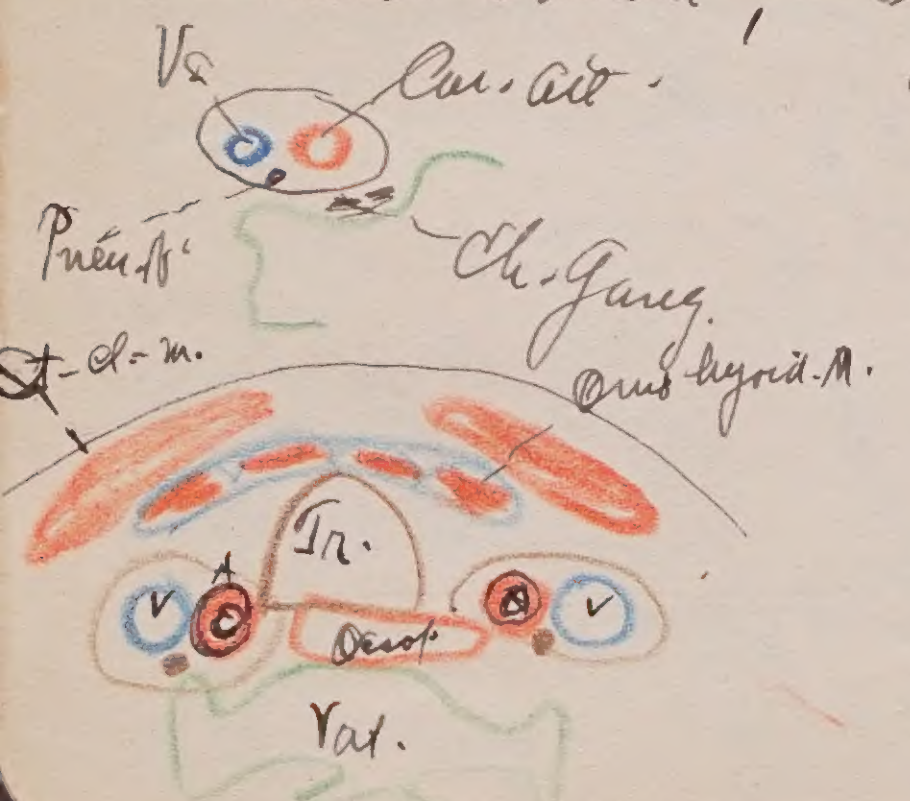

Anteriorly — Sterno-cleido-mastoid Muscle, Depressors of Hyoid bone, with their fascia including them.

Internally — Trachea and Oesoph. Recurrent Laryngeal Nerve.

The artery grooves the Parotid Gland

Externally – the Ext. Jugular Vein only
In Sup. Carotid △, – only anterior edge of ~~artery~~ muscle over artery.

May 21/(62).

Next Incision for Common Carotid Artery – above Omo-hyoid Muscle in Superior Carotid △. Omo-hyoid crossed under Sterno cleido Mastoid at level of Cricoid cartilage. The only thing to cut through is vascular sheath.

External ~~Cartilage~~ Carotid Artery – Begins at upper level of Cricoid cartilage – runs up to midway between ∠ of jaw and mastoid process; enters parotid; bifurcates int. Int. and Ext. Maxillary arteries.

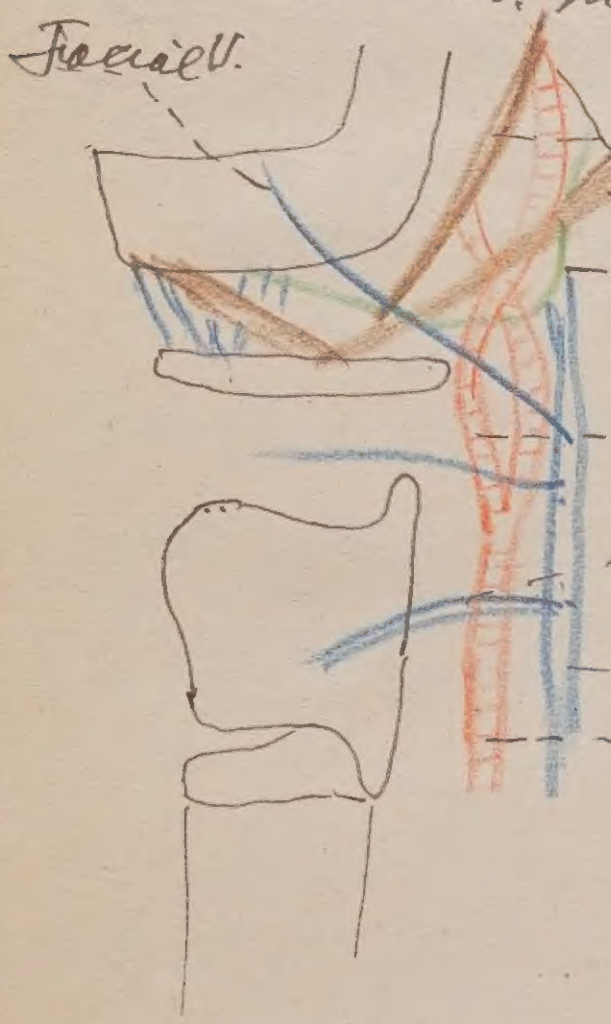

Muscles crossing it: – Digastric and Stylo-hyoid (Safe so long as these Muscles are beneath operation). Runs betw. these Muscles above any Stylo-glossus and Stylo-pharyngeus Internally.

Hypoglossal ~~Nerve~~ crosses over Ext. Car. above hyoid bone – to fat & tongue

Return veins Sup. thyroid, Facial.

Branches: –
Sup. Thyroid A. – Branch to Thyroid Gland. – of Hyoid Bone; – difficult to ligate. Most Superficial Ther, Crossed by Depressor

Lingual (to tongue), comes off above Hyoid Bone, disappears in substance of Hyoglossus Muscle. Appears in floor of Lingual Triangle (Bounded above by Hypoglossal Nerve below by post. belly Degastric, Mylo hyoid.



May 22/66.



Ranine Artery - does not anastomose with its fellow of the other side of tongue. One side of the tongue may be excised without haemorrhage from the other side.

Facial artery. - Br. Ext. Carotid - courses along ∠ of jaw, crosses jaw at ant. edge of Masseter muscle. - takes a circuitous course to ∠ of mouth, terminating in Angular art. edge. Superficial where it crosses ∠ of jaw between edge of Masseter muscle and jaw. In immediate relation to pharynx. - Pharyngeal Branch. Tonsillar Branch.

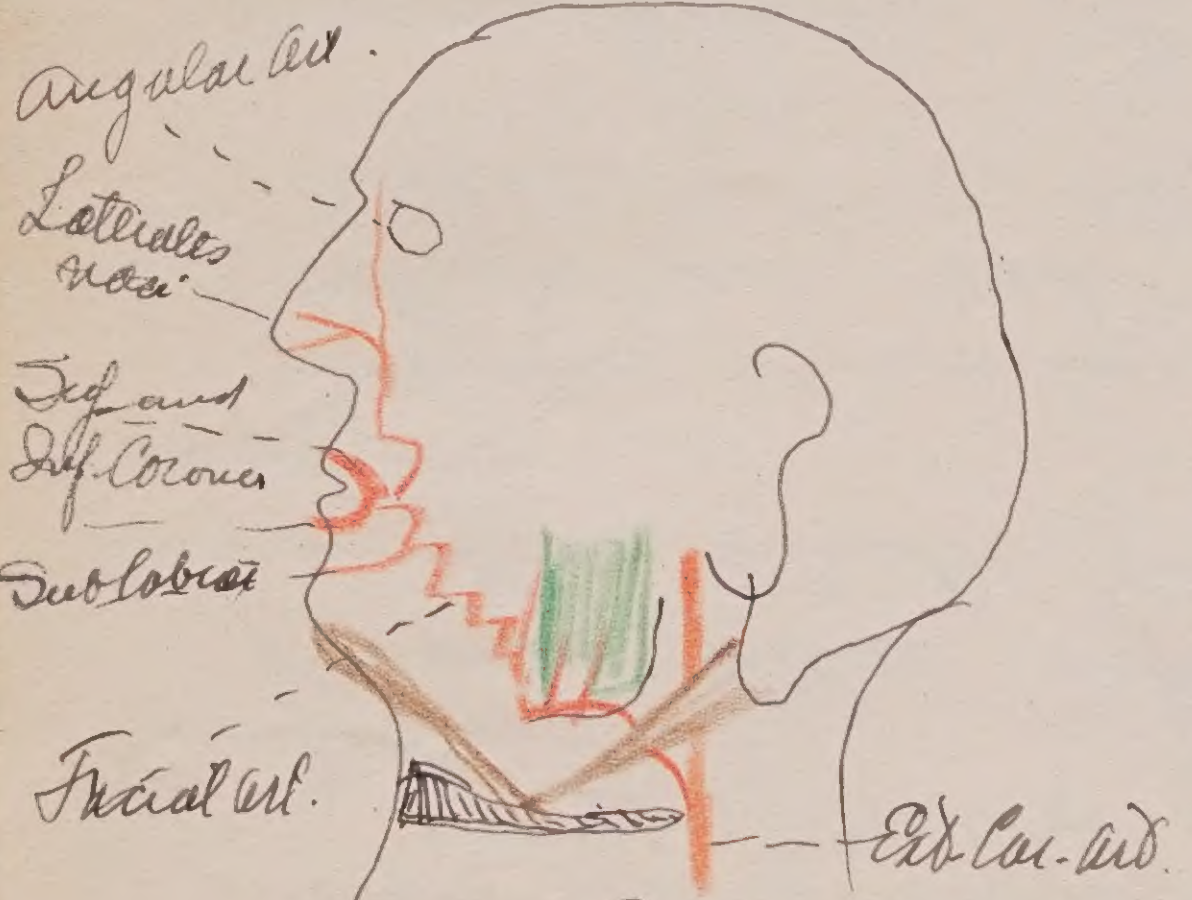

Tonsillar branch forms a ramification around the tonsils.
Submaxillary branch
Sublingual branch

Facial portion:–
Coronary arteries (Superior and Inferior) – around the mouth; situated under mucous membrane.
Sublabial – lower lip.
Laterales Nasi – side of nose
Angular

Muscular Branches – Buccal, Masseteric.
Ligate Facial artery below angle of jaw.

Terminal Branches.
Internal Maxillary –
Superficial Temporal –

Internal Maxillary – to Spheno-maxillary fossa – supplies floor of orbit, palate, pharynx.
Comes off in substance of Parotid gland winds around neck of condyle of jaw; runes directly on to Spheno-maxillary fossa, where it breaks up into terminal branches:–
Infra-orbital branch
Nasal branch – pterygo-palatine foramen

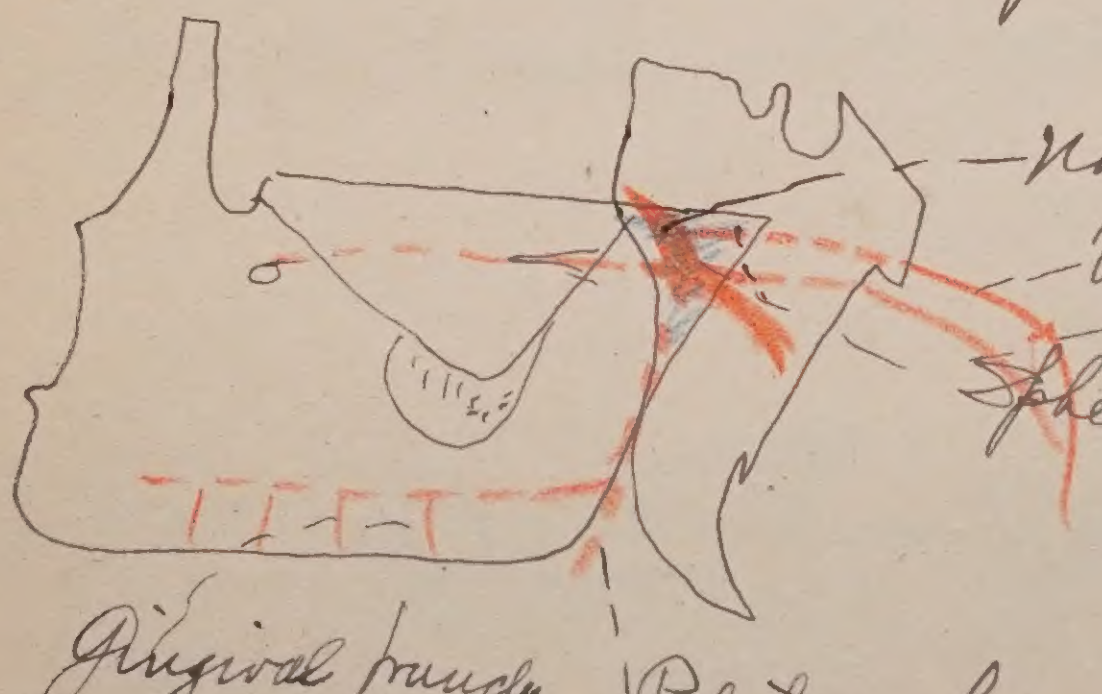

Palatine Branch
Vidian artery.
Posterior Dental branches
Gingival branches (to Gums)

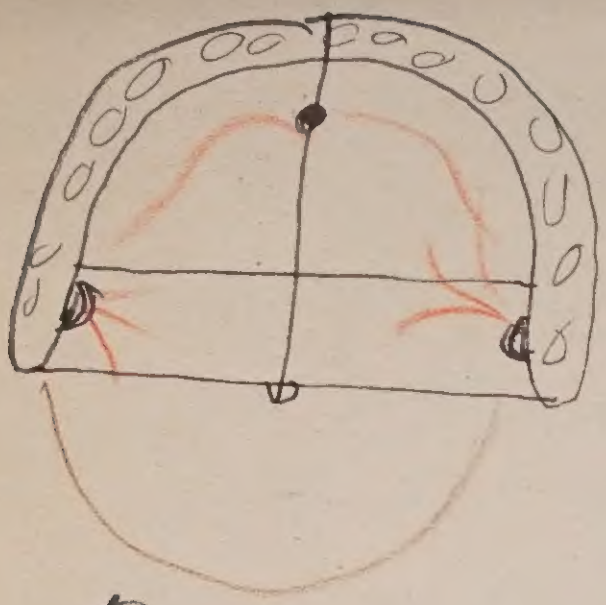

Relations:-

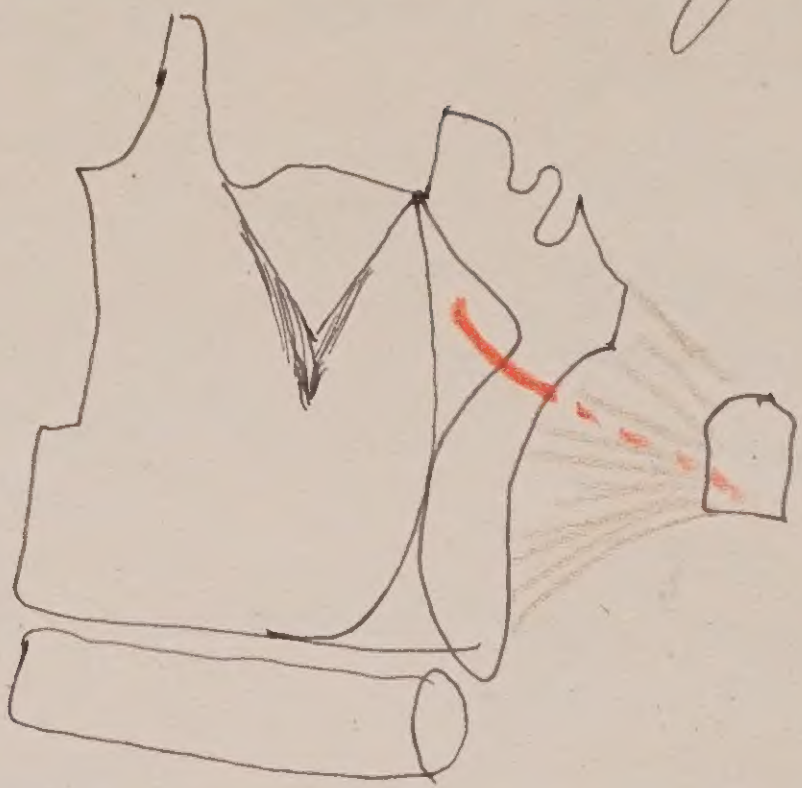

Important Branches.
Middle Meningeal - from Internal Maxillary - Enters foramen spinosum: in gr. wing of Sphenoid bone, breaks up into Ant. and Post branch.

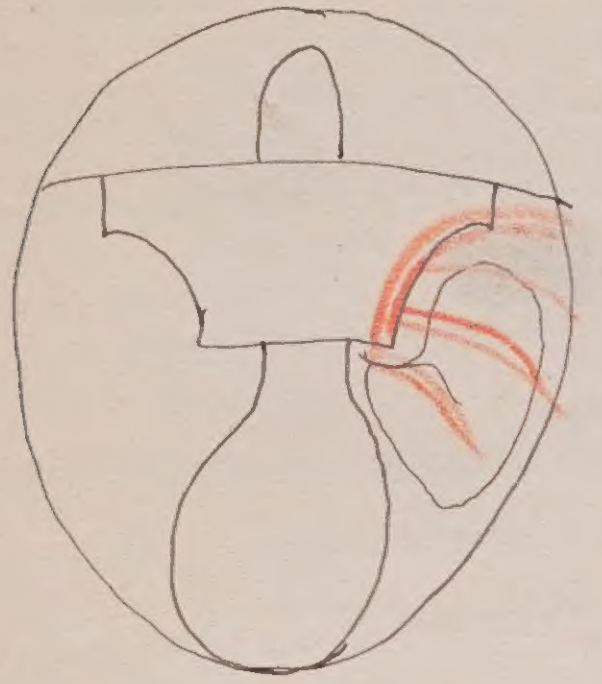

At. ant. and Inf. angle this artery frequently tunnels the bone; below and above is related to dura mater.

Back of Ext angular process of eye, 1 1/4 in. back, 1 1/4 in. up. paralleling Zygoma, gives ant. Inf. ∠ of Parietal bone.

Lesser Middle Meningeal - passes in through For. Ovale, with Inf. max. division of 5th Nerve.

Inferior Dental - comes off as it winds around the neck; supplies teeth and lower jaw.
Tympanic -
Masseteric -
Deep Temporal -
Pterygoid -

Superficial Temporal - Runs up in Parotid gland; becomes superficial at upper limit. running over zygoma; then runs up in scalp in Superficial fascia, giving off anterior and posterior branches. May cause great haemorrhage when cut.

May 23/06. Superficial Temporal artery becomes apparent when it crosses over 3rd root of zygoma. may be compressed on the bone.
Auricular branches
Transverse Facial
~~Stylo mastoid~~

Occipital Artery - comes off at a definite point from Ext. Carotid - lower edge of Digastric Muscle. passes beneath it to the Occipital groove (placed deeply); winds backward, pierces insertion of Trapezius m. at Sup. curved line, about 1 inch lateral to ~~near~~ Ext. Occipital Protuberance
Collateral anastomosis -

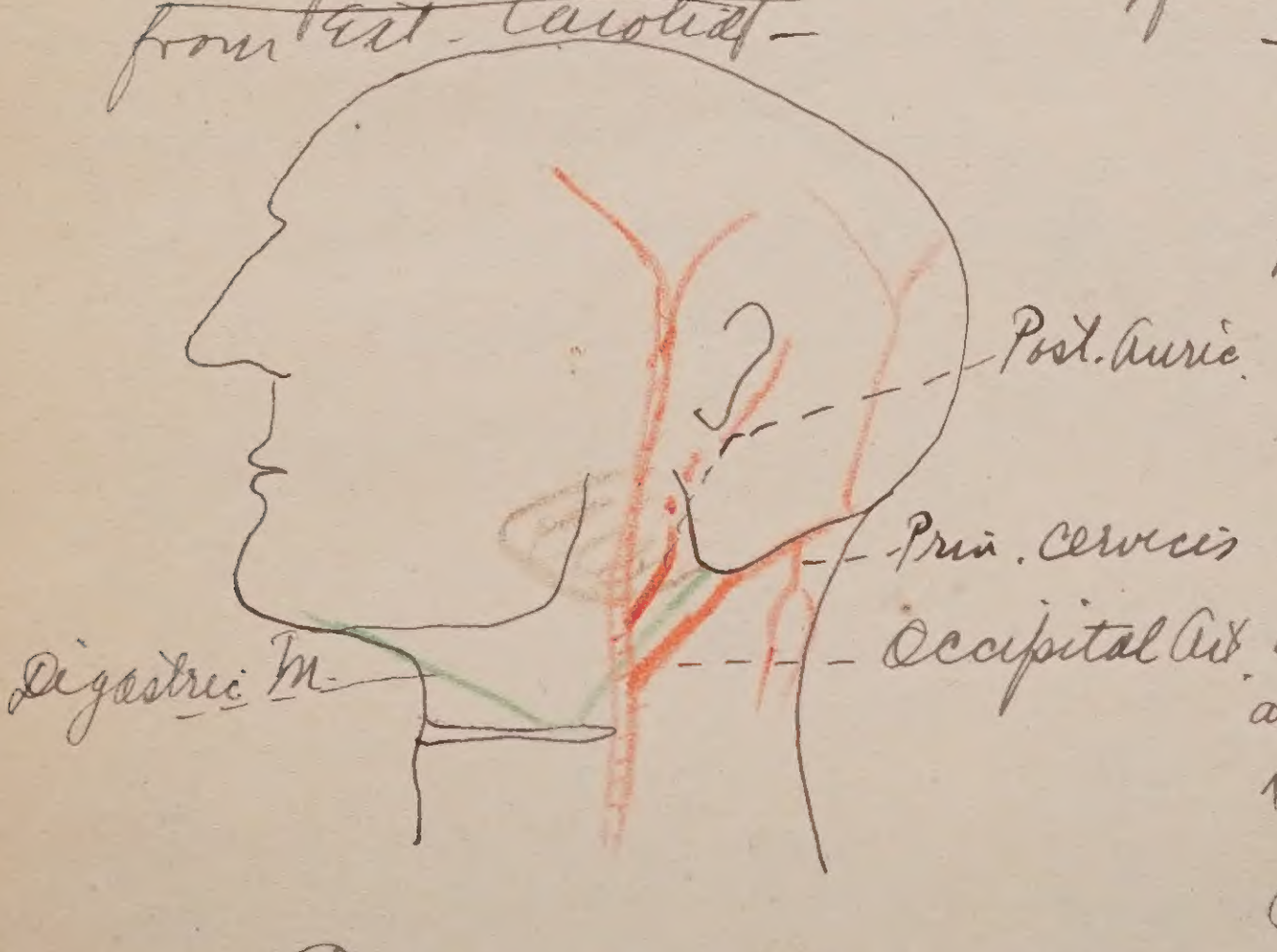

with Princeps cervicis, (comes off deeply beneath Complexus muscle; dividing into Superficial and Deep branches

Posterior Auricular – come off at upper border of Digastric muscle. deeply placed; becomes superficial just behind the Ear.

Subclavian Artery – varies on 2 sides.
In neck – begins at Sterno-clavicular articulation, deeply placed. arches upwards, and becomes Axillary at outer edge of 1st rib at about mid-clavic. point. 3 portions, divided by Scalenus anticus muscle.

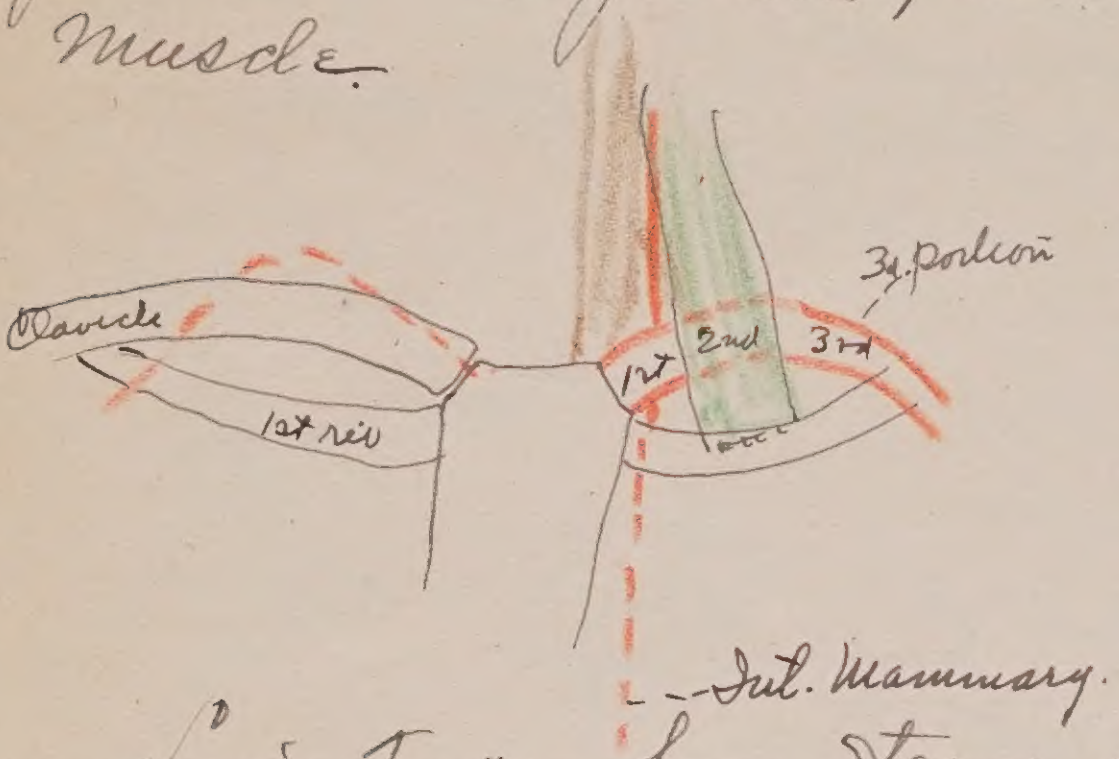

1st – internal to Scal-ant
2nd behind " "
3rd. External to " "

In 1st and 2nd portions rests on pleura.
3rd portion rests on 1st rib.

Linear Guide – from Sterno-clav. Artic. to Mid-clavic. point, arching with Concavity upward.
Muscle Guide: – outer edge of Sterno-cleido-Mastoid muscle (Scalenus ant. behind Clavicular head of St-Cl-Mast. muscle). Behind fascia, Superficial arteries and Veins.



Branches, as a rule, from 1st portion.
Internal mammary – runs down at lateral Edge of Sternum about ½ in. from it. – Ends in 2 branches – Superior Epigastric and Musculo-phrenic. Int. Mammary next to Cartilages of ribs, and Triangularis sterni muscle beneath it.

Vertebral artery – from 1st portion – runs up between Longus colli and Scal. anticus – disappears in foramen of 6th cervical vertebra opposite Cricoid Cartilage; the most posteriorly placed. runs up in transv. processes of vertebra – into foramen magnum, unites with its fellow of opposite side to form Basilar artery (runs in groove of Pons Varolii) – then terminates as Posterior Cerebral.

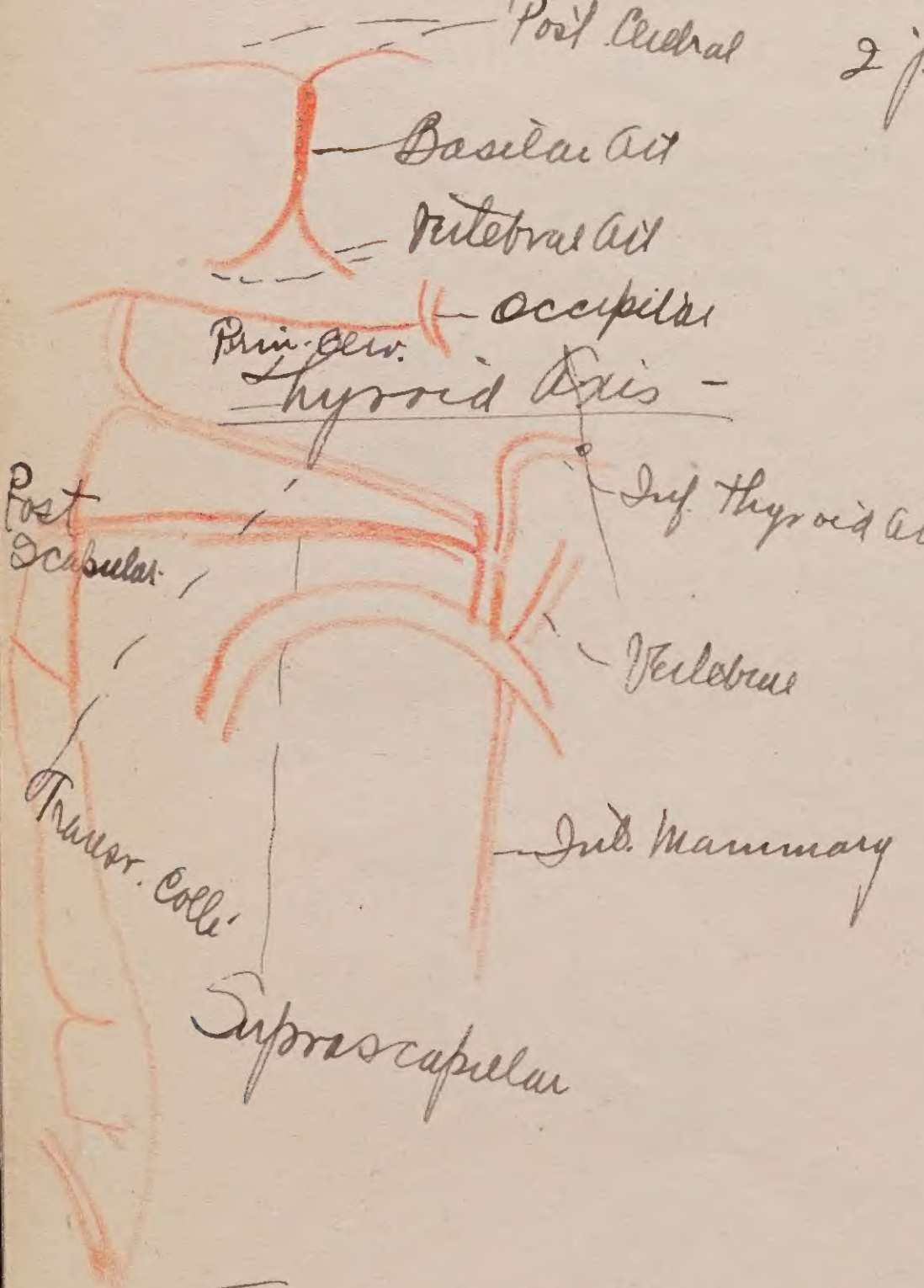

2 points of attack: –
1st Cervical Transv. Process.

Inf. thyroid art. – very circuitous course – runs up on Scal. ant. to just below Cricoid Cart. where it swings in. Passes behind vasc. sheath, sympathetic chain & upon 2nd cervical ganglion – Thyroid ganglion. The Vertebral artery is only one behind.

Transversales Colli – runs obl. upwards and forwards passing in front of Scal. Ant. Muscle – divides into 2 branches – Ascending Cervical (anast. with Superf. branch of Princeps cervicis) – and Postscapular passing down (anast. with Subscapular.

Suprascapular – runs over Scal. ant. – to Suprascapular notch – (anast. with Dorsalis scapulae and Subscapular.

Sup. br. from
Pr. Cerv. from Occipital



Superior Intercostals — Anast. with br. from aorta. Superior branch anast. with Deep branch of Princeps cervicis.

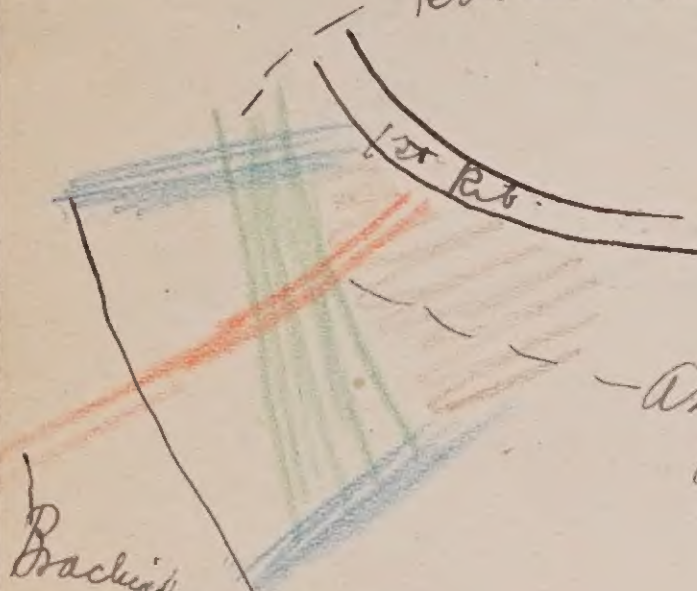

Axillary Artery — Contin. of subclavian; begins at outer edge of 1st rib; terminates at base of axillary space (where it becomes Brachial).

Linear Guide — upper point mid-clavic. point; outer point is junction of ant. 1/3 of Post. 2/3 of line drawn from Pectoralis major (outer wall) to Latissimus dorsi. (Not Important).

Muscle Guide — in 3rd portion of artery — posterior border of Coraco-brachialis. First come on axillary vein, and then artery.

Divided into 3 portions by Pectoralis minor.

Internal — Covered by Costo-coracoid membrane.
Behind = By Pect. minor.
External — Deltoid and Pect. major.

Subclavian fossa between Deltoid and Pectoralis major — lying above Costo-Coracoid membrane.

Axillary vein to thoracic side of artery in all its course.

In 1st portion, Brachial plexus is above artery; in 2nd and 3rd portions, surrounds the artery.

Branches:—

1st – Axillary Axis (Acromio-thoracic artery) divides into

Acromial

Thoracic

Humeral – between Deltoid and P. major.

Superior thoracic – to pectoral muscles.

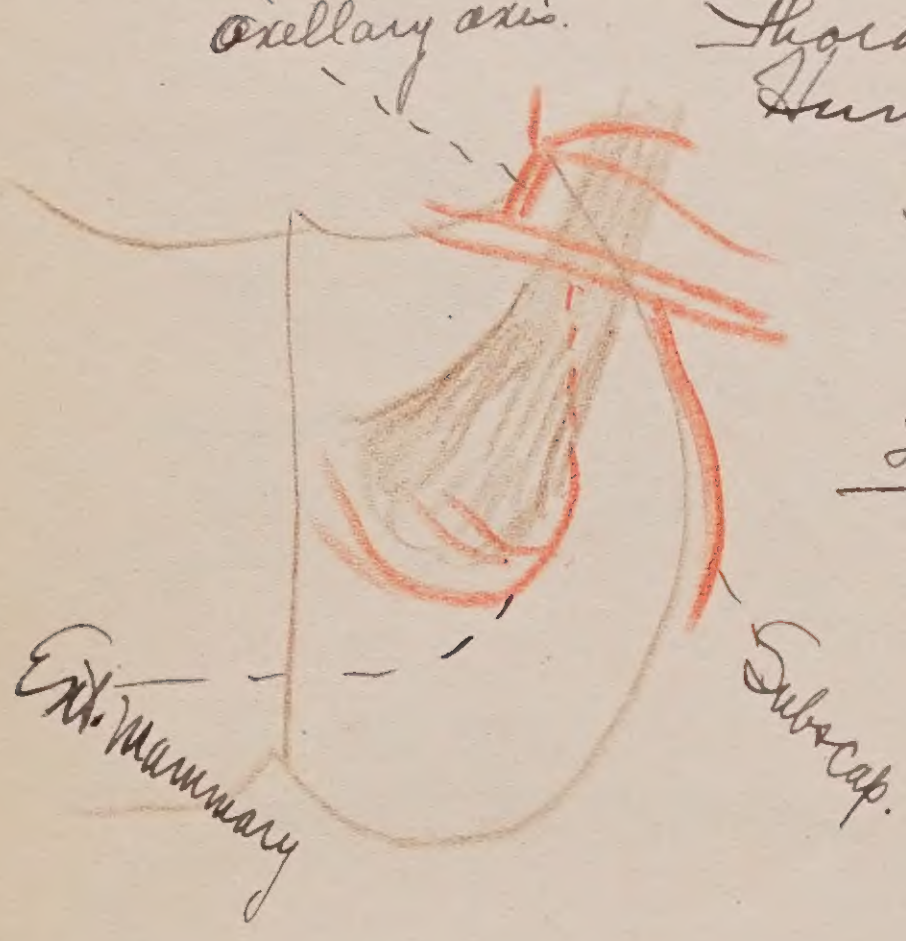

2nd portion –

External Mammary – winds down under P. minor along outer edge of Pect. major – to go to Mammary gland.

Alar thoracic – to glandular structures of axilla

3rd portion –

Subscapular – runs along axillary edge of Scapula; or axillary edge of Subscapularis muscle

Anastomoses with Posterior Scapular (from Transv. colli) (Guarded by Subscapular vein).

Dorsalis Scapulae.

Circumflex { Large Posterior / Small Anterior

Passes around surgical neck of humerus, branches to the shoulder joint

Collateral Anastomosis

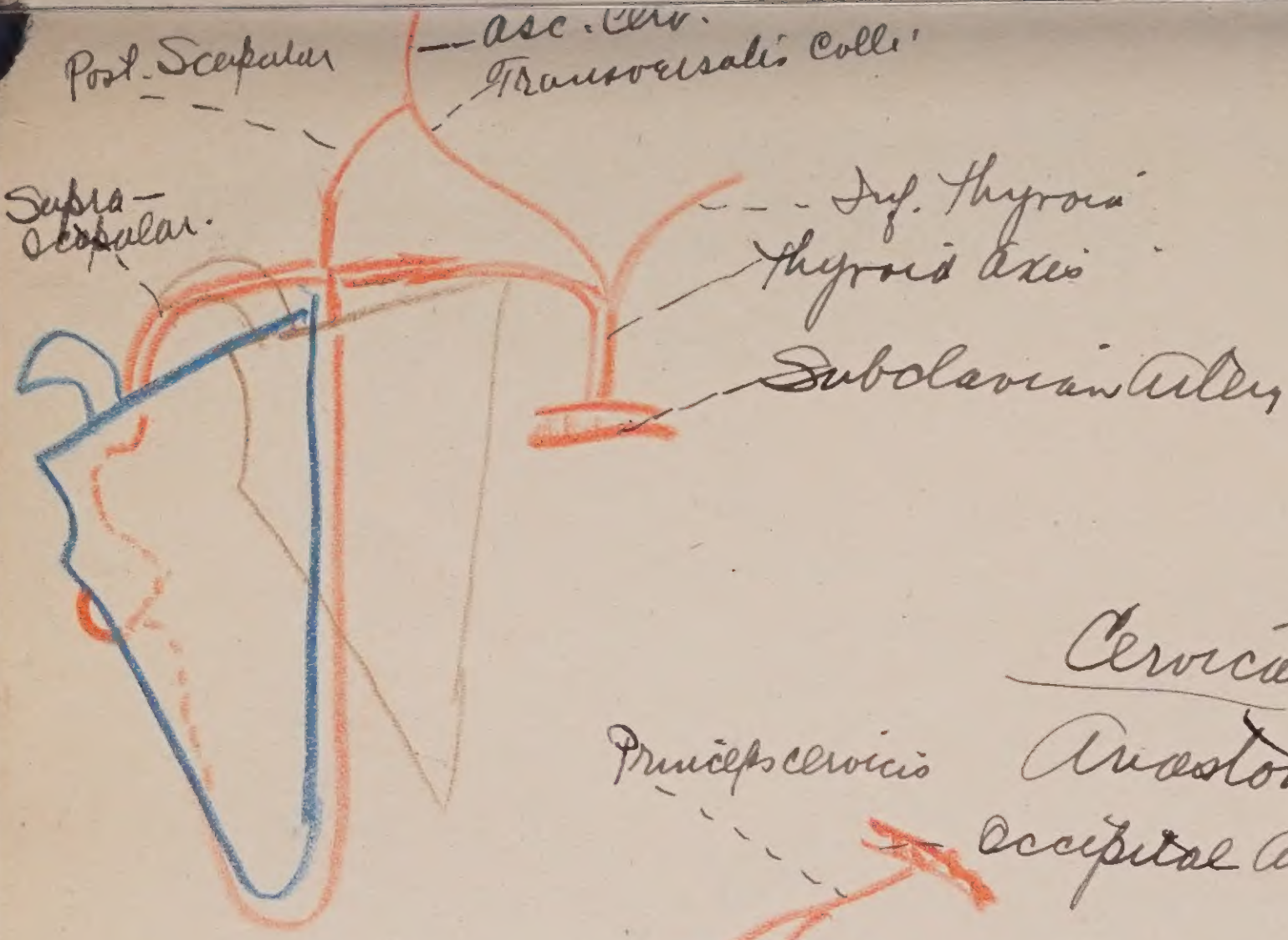

Cervical Collateral Anastomosis

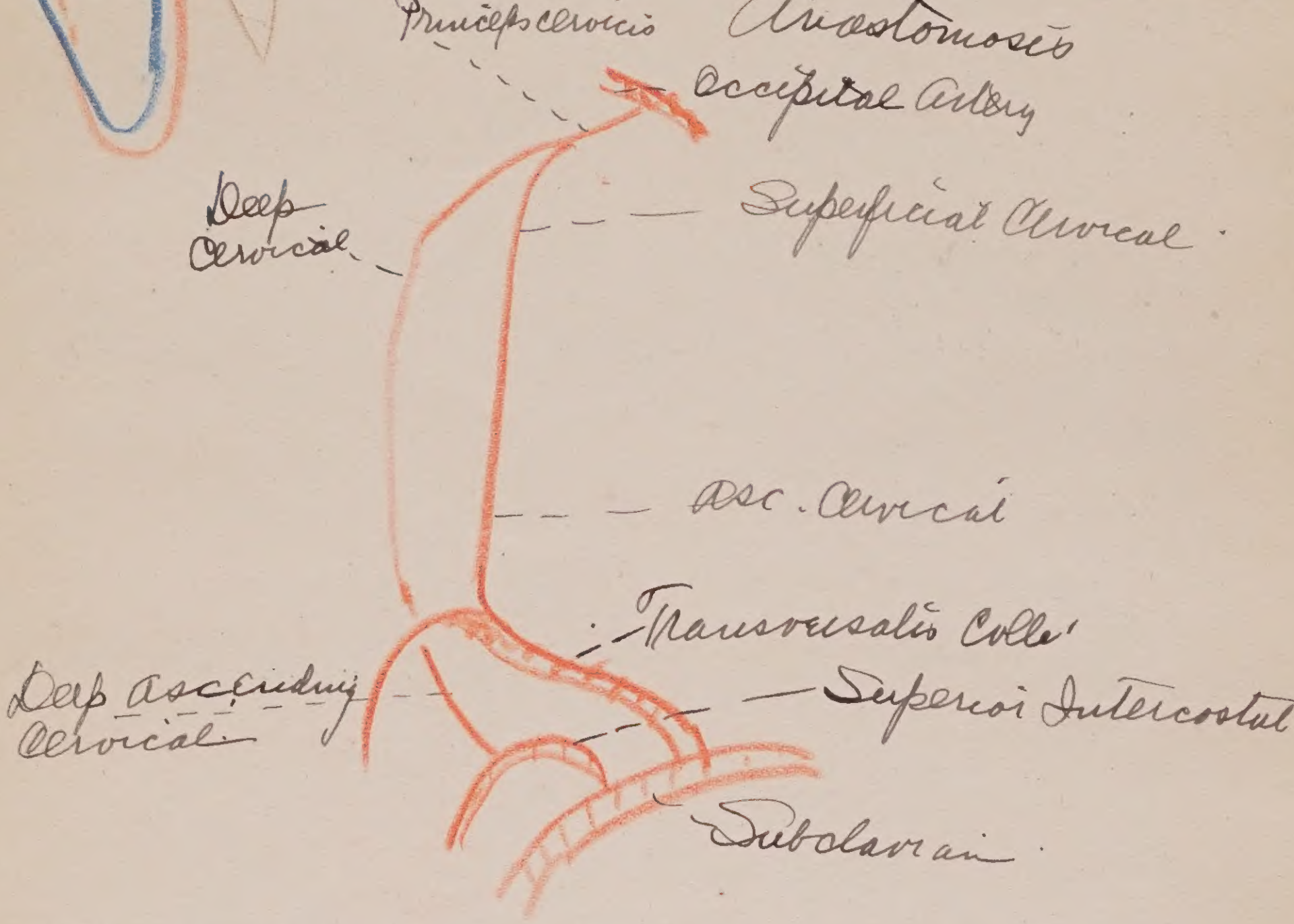

Brachial Art – begins at base of axilla; runs down in Internal Bicipital Furrow.

Knee Joint - a mixed joint
Ginglymoid joint.

Bones
Femur
Tibia
Patella.

Flexion

Extension

In semi-flexion Internal and
External Rotation

Ankle-Joint - a pure hinge
Joint - simply flexion and
Extension
Bones - Tibia, fibula, astragal



External Rotators — practically all other muscles of hip.

Gluteus maximus
" med. } posterior
" min. } fibres
&c, etc

Arterial Supply
: Femoral-branches in front
Circumflex
Gluteal. Sup e Inf
Sciatic

Nerves: Anterior Crural
Obturator
Sciatic
Superior Gluteal

Prevents too great extension of hip-joint. Allows upright position in human being without tiring muscles.



Ligamentum teres—
Below transverse ligament—a mass of fat covered by synovial membrane—a cavity allowing entrance of vessels and nerves.

Ligamentum teres—attached to sides of ~~Acetabulum~~ Cotyloid notch and transverse ligament.

~~External~~ Interior Rotation—
- Tensor fasciae femoris
- Gluteus medius } anterior
- Gluteus minimus } fibres
- Ilio-psoas Muscle (an Internal Rotator)

When neck of femur is broken, the Ilio-psoas becomes an External Rotator.

Hip-Joint

Ball and Socket - firmly in opposition

Bones - Innominate with head of femur

Capsular reinforced by Y-ligament or Ilio femoral ligament

Transverse ligament

Ligamentum teres

Cotyloid ligament - fibro-cart. deepening joint

Capsular ligament.

Brim of Acetabulum above;

Below - to transverse ligament

Below, to anti. spinal line, lesser & gr. trochanters and neck of femur.

Fibres run obliquely downwards and inwards.

Ilio-femoral - strongest lig. of body from ant. inf. spine of Ilium - bifurcates - one division to greater and one to lesser trochanter.

Ligaments

Capsular

Anterior

Posterior

External.

Internal

Movements

Flexion - by tendons of muscles in front

Extension

Abduction

Adduction.

Arteries

Radial

Ulnar

Ant. Interosseous

Post. Interosseous

Deep Palmar Arch

Nerve Supply:

Ulnar

Deep Palmar Interossei

Arterial Supply –

Interior profunda (inner
Exterior profunda (extern
Post. Inteross. Recurrent
Ant. Radial
Post Ulnar

Nerve Supply –
Musculo-Spiral
Musculo-Cutaneous
Median
Ulnar

Wrist Joint –
Condyloid
Radius Triangular fibro cart. (ebon
Scaphoid Semilunar Cuneiform



All movements except rotation
no rotation

Movements
Flexion
Brachialis anticus
Bicep - Assist. by muscles from inner condyle.
Extension
Triceps.
Muscles from Ext. condyle which ... [illegible]
Radio Ulnar - { Pronation
Supination

X Pronator
Pron. radii teres
F. carpi radialis
F. sublimis digit.
possibly Palmaris longus
Pronator quadratus

Supinator
Bicep
Supinator brevis.
Supinator longus
Ext. carp. rad. longior & brevior

When forearm is supinated, the Supinator longus acts as a pronator

Elbow Joint –
Complex Joint — Various movements

Bones –
Trochlear Surface of Humerus
Capitellum " "
artic. with Greater Sigmoid
Cavity of Ulna and cup-shaped
head of Radius and Circumference
of head of radius with lesser
Sigmoid cavity of Ulna
3 sets
Humero-Ulnar – hinge
Humero-Radial – a gliding joint
Radio-Ulnar – a pivot. joint.
Ligaments –
Capsular – divided
Anterior – weak
Posterior – "
Internal Lateral – strong
triangular "deltoid" lig.

External Lateral – weak.
Orbicular Ligament – attach.

[illegible] Cartilage — Deepens cavity

Coraco-acromial ligament (accessory) prevents upward displacement of shoulder-joint.

Muscles acting upon Joint

Flexors

Extensors

Internal Rotators

External Rotators

Pectoralis major
Teres minor
Latissimus dorsi

Adductors

Abductors

Arterial and Nerve Supply—

Circumflex
Suprascapular } Arteries and Nerves.

Major Joints -

(1.) - Kind of Joint

Shoulder Joint - Ball & Socket - has all movements;

Flexion
Extension
Abduction
Adduction
Internal Rotation
External Rotation.
Circumduction

(2) Bones entering into articulation
Head of Humerus
Glenoid cavity of Scapula

(3) Ligaments
Capsular -
Transverse Humeral
Coraco-Humeral
Condyloid Ligament

Capsular - Around glenoid Cavity - to anatomical neck, greater and lesser tuberosities and where it arches over neck of humerus - transverse ligament

Peculiarity - loosely attached.

Coraco-humeral. base of coracoid proc. to Gr. tuberosity. Strengthens capsule above.

Ing on Perineum
Boundaries
2. Triangles
Musculature

Dorsal Interossei	4 in number. Bipenniform, arising by 2 heads from adjacent sides of Metatarsal bones between which they are placed.	Inserted into bases of 1st phalanges, and into aponeurosis of common Extensor tendon.	External Plantar Nerve	Abduct toes from axes of 2nd toe. Also flex proximal phalanges & Extend the 2 terminal phalanges.
Plantar Interossei	3 in number lie between the Metatarsal bones. - single muscles, Connected with but 1 Metatarsal B. Arise from base & inner sides of Shaft of 3rd, 4th & 5th Metatarsal B.	~~Base and inner sides of shaft of 3rd, 4th, & 5th Metatarsal bones~~ Inner sides of bases of 1st phalanges of same toes & into aponeurosis of Comm. Extensor tendon	External Plantar Nerve.	Adduct 3rd, 4th & 5th toes toward 2nd toe. Also flex the proximal phalanges & Extend the 2 terminal phalanges.

Muscles-	Origin-	Insertion-	Nerve-Supply	Action.
3rd Layer				
Flexor brevis hallucis	Inner part of under surf. of Cuboid; from contiguous portion of Ext. Cuneiform, & prolongation of tend. of Tib. posticus	Divides into 2 portions, inserted into inner & outer sides of base of 1st phal. of g. toe, a sesamoid being developed in each tendon at its insertion	Internal Plantar Nerve.	Flexes the Great toe upon the foot.
Adductor obliquus hallucis	Tarsal extremities of 2nd, 3rd & 4th Metatarsal bones, & from sheath of tendon of Peroneus longus.	Inserted (with outer portion of F. brev. hallucis) into outer side of base of 1st phal. of gt. toe.	External Plantar Nerve	Adducts gt. toe toward 2nd one. also flexes toe.
Flexor brevis minimi digiti	Base of Metatarsal of little toe, & from sheath of Peroneus longus	Base of 1st phalanx of little toe on its outer side	"	Flexes little toe & draws its Metat. downward & inward.
Adductor transversus hallucis. (= Transversus pedis)	Inferior Metatarso-phalangeal ligaments of 3 outer toes (sometimes from only the 3rd & 4th) and from transverse lig. of metatarsus.	Outer side of 1st phalanx of Great toe, its fibres being blended with tendon of insertion of Add. obl. hallucis.	"	Approximates all the toes, & thus increases transv. arch of Metatarsus
4th Layer-				
Interossei muscles.	Similar to those in the hand, but are grouped around the middle line of <u>second</u> toe. Seven in number four dorsal interossei three plantar interossei			

Plantar Region- 1st Layer.				
Abductor hallucis	Inner tubercle on under surf. Os calcis; Int. Annular Lig.; Plantar fascia; Intermusc. Septa.	Inserted (with innermost tendon of F. brev. hall.) into inner side of base of 1st phalanx of G. toe.	Internal Plantar Nerve.	Abducts G. toe from the others; also flexes proximal phalanx.
Flexor brevis digitorum	Inner tubercle of Os calcis; central part of plantar fascia; & inter-muscular septa.	Tendons (4) divide to allow passage of F. long. digit., unite, & divide again, to be inserted into sides of 2nd phalanges about their middle.	"	Flexes 2nd phalanx upon the 1st; may also flex 1st & bring the toes together.
Abductor minimi digiti	Very broad origin; from Outer tubercle of Os Calcis, from under surf. betw. 2 tubercles from fore part of inner tubercle; plantar fascia; Interm. septum.	Inserted with short flexor of little toe into outer side of base of 1st phalanx of little toe	External Plantar Nerve.	abd. little toe from others; also flexes proximal phalanx.
2nd Layer				
Flexor accessorius	Arises by 2 heads: (sep. by l. plantar lig.) Inner (muscular) in inner concave surf. of Os calcis below groove F. l. hall. Outer (tendinous) to outer surf. Os calc. in front of lesser tub. & to l. plantar lig.	2 portions join and are inserted into outer marg. & upper & under surfaces of tendon of Flexor long. digitorum	External Plantar Nerve.	Assists l. flexor of toes & converts obl. pull into a direct backward pull.
Lumbricales	4 muscles arising from tendons of long flexor; Each arising from 2 tendons except the internal one.	Tendons pass on inner side of 4 lesser toes, & are inserted into Expansion of long Extensor tendon on dorsum of 1st phalanx of corresp. toe.	3 outer by Ext. Plantar & Inner-most by Int. Plantar	Flex proximal phalanx, & aid in straightening 2 term. phal.

Muscles-	Origin	Insertion	Nerve-Supply	Action.
Fibular Region				
Peroneus longus	Head & upper 2/3 outer surf. shaft of fibula; deep surf. of fascia; Interm. septa. occasionally by a few fibres from outer tuberosity of tibia.	Tendon passes behind Outer Malleolus, passes obl. forw. across outer side Os calcis, below its peroneal tubercle, along groove the under surf. cuboid; then crosses sole of foot obliquely; inserted into outer side base of Met. of g. toe and Int. Cuneif. Occasionally sends a slip to base of 2nd Metatarsal bone.	4th & 5th Lumbar and 1st Sacral Nerves thro Musculo-Cutaneous branch of Ext. Popliteal Nerve.	Extend foot upon leg. also everts sole of foot. Taking fixed point below, the Peronei serve to steady leg upon the foot.
Peroneus brevis	(Lies beneath Peroneus longus). Arises from lower 2/3 ext. surf. shaft of fibula & Inter-Muscular septa.	Tendon runs behind Outer Malleolus, then passes to outer side of Os calcis above tendon of Per. longus (being separated by the peroneal tubercle), inserted into tuberosity at base of Met. of little toe, on its outer side.	"	Extend foot upon leg.
Muscles of Foot				
Dorsal Region.				
Extensor brevis digitorum	Fore part of upper & outer surf. of Os calcis in front of groove for Peroneus brevis; from Ext. Calcaneo-Astragaloid Lig.; & com. limb of Y-	Passes obliquely across dorsum of foot, term. in 4 tendons. Outer (largest) in dorsal surf. 1st phalanx g. toe	Anterior Tibial Nerve.	Accessory to Long Extensor Ext. phal. of 4 inner toes. but acting only on

Flexor longus hallucis.	Lower 2/3 post. surf. shaft Fibula, Inteross. Membr.; Interm. septum. Fasc. cov. Tib. post.	Fibres pass obl. down. & backw. Tendon occupies groove on post. surf. lower end of tibia; groove on post. surf. Astrag.; groove beneath Susten. tali of Os calcis, to base of last phal. of great toe.	5th Lumbar & 1st & 2nd Sacral thru Posterior Tibial.	Flex phalanx of g. toe. Also extend foot upon the leg.
Flexor longus digitorum	Post. surf. shaft of tibia, immed. below Obl. line to within 3 in. of its extremity	Tendon passes behind Int. Malleolus with Tib. posticus, passes obl. forw. & outward over Flex. l. hallucis, is joined by Flexor accessorius, divides into 4 tendons, inserted into bases of last phal. of 4 lesser toes, passing thro fissure in tendon of F. brevis digitorum.	5th Lumbar and 1st Sacral	Flex phal. of toes Also extend foot upon the leg.
Tibialis posticus	Whole post. surf. Inteross. Membr. except lowest part; Outer portion post. surf. shaft tibia; Upper 2/3 Int. surf. of Fibula; also a few fibres from deep transverse fascia & from Interm. septa.	Tendon passes behind Int. Malleolus, then over Int. Lat. lig. then beneath Inf. Calcaneo-Navicular Lig.; inserted into tuberosity of the Navicular and Int. Cuneiform bones.	5th Lumbar and 1st Sacral	Direct extensor of foot; also (in conjunc. with Tib. anticus) inverts the foot; antagonizing the foot.

Muscles	Origin	Insertion	Nerve-Supply	Action.
Peroneus tertius	Lower ¼ ant. surf. fibula; lower part inteross. membr.; Intermuscular septum between it & Per. brevis. (is a part of Ext. long. digitorum — its 5th tendon).	Dorsal surface of base of Metatarsal of little toe	4th & 5th Lumbar & 1st Sacral thro Ant. Tibial Nerve.	Flexor of foot at Ankle-joint.
Poster. Tibio-Fibular				
Gastrocnemius (= superficial layer.)	Arises by 2 heads. Inner (larger) from upper & back part inner condyle & adjacent part of femur. Outer (smaller) from outer side Ext. cond. & post. surf. femur above condyle.	Aponeurosis unites with tendon of Soleus forming the Tendo Achillis.	1st & 2nd Sacral Nerves.	Extend foot at ankle-joint. Also flexes femur on tibia.
Soleus (middle layer)	Back part head fibula & upper part of post. surf. of its shaft; oblique line of tibia & middle ⅓ int. border.	Aponeurosis joins with tendon of Gastrochemius to form the Tendo Achillis	5th lumbar & 1st & 2nd Sacral thro Int. Popliteal & Poster. Tibial	Extensor of foot at ankle. In standing prevents body from falling forward.
Plantaris	Lower part of outer prolongation of linea aspera, & post. lig. of knee-joint. (very small M.)	Tendon runs along inner border of Tendo Achillis, & inserted into Os Calcis.	4th & 5th Lumbar & 1st Sacral thro Int. Popliteal.	Accessory to Gastrocnemius.
Deep Layer.				
Popliteus	Arises by a strong tendon from deep depression on outer side of Ext. Condyle of femur, & Ext. Lat. Lig. Knee-	Inner ⅔ of Δ surf. above obl. line on post. surf. shaft of tibia.	"	Flexes leg on thigh. When leg is flexed rotates tibia inward.

	Also from inn. surf. obt. memb. except at its post. part, from tendinous arch which completes canal for passage of obt vessels & nerve.			
Gemellus superior	Outer surf. spine of Ischium	Blends with upper part of tendon of Obtur. int. and is inserted into inner surf. of Great trochanter	"	"
Gemellus inferior	Upper part of tuberosity of Ischium	Blends with lower part tend. Obt. int. and inserted into in. surf. gr. troch.	5th lumbar & 1st sacral	"
Quadratus femoris	Upper part of Ext. lip of tuberosity of Ischium	Upper part of linea quadrata = line crossing the post. intertroch. line	"	"
Obturator Externus	Margin of bone around inner side of Obt. foramen. Inner $\frac{2}{3}$ outer surf. Obt. memb. & from tendinous arch.	Digital fossa of femur		"

Muscles of Leg

Ant. Tibio-Fibular.

Tibialis anticus	Outer tuber. & upper $\frac{2}{3}$ Ext. surf. shaft of tibia; Interosseous memb.; deep surf. of fascia, & inter-muscular septum	Inner & under surf. Int. Cuneiform and base of 1st Metatarsal	4th & 5th Lumbar & 1st Sacral thro Ant. Tibial nerve.	Flexor of foot at ankle-joint also inverts foot.
Extensor longus (proprius) hallucis	Ant. surf. Fibula for middle $\frac{2}{4}$, internal to Ext. l. digitorum also from Inteross. Membrane	Base of last phalanx of Great toe	"	Extensor of Great toe; also flexes foot upon leg.
Extensor longus digitorum	Outer tuber. tibia; Upper $\frac{3}{4}$ ant. surf. Fibula; Interosseous Memb. Deep surface of fascia Intermuscular Sept.	2nd & 3rd phalanges of four lesser toes. Receive fibrous expansion from Interossei & Lumbricales	"	Extend phalanges of the toes.

Muscles-	Origin-	Insertion-	Nerve-Supply	Action
Gluteal Region-				
Gluteus maximus	Sup. curv. l. of ilium & bone above it. Post. surf. lower part of Sacrum, lower side of Coccyx. Apon. of Er. Spinae, Gr. Sacro-sci. lig. & fasc. cov. G. medius.	Superficial fibres into fascia lata on outer side of thigh. Deep fibres, into rough line from Gr. trochanter & linea aspera between Vast. ext. & Add. mag.	5th Lumbar & 1st & 2nd Sacral, through Inferior Gluteal Nerve from Sacral plexus.	Extends femur. Causes body to regain Erect posit. by drawing pelvis backward. Tensor of fasc. lata. Steadies femur on tibia while standing
Gluteus medius	Outer surf. of ilium, betw. Sup. & Middle curved lines, and from outer lip of crest between them	Oblique line on outer surface of Gr. trochanter.	4th & 5th Lumbar & 1st Sacral thro. Sup. Gluteal	Abduct thigh. Support body on one limb.
Gluteus minimus	Outer surf. ilium, betw. Mid. & Inf. curved lines, and from margin of Gr. Sacro-sciatic notch.	Impression on anterior border of Great trochanter	"	"
Pyriformis	Front of sacrum by 3 fleshy digitations betw. 1st, 2nd & 3rd & 4th ant. sacral foramina; a few fibres from margin of Gr. Sac. sciat. foramen & ant. surf. Gr. Sacro-sciatic ligament	Passes out thro. Gr. Sacro-sciatic foramen. Inserted into upper border Great trochanter. Often partly blended with tend. of Obt. int. & Gemelli.	1st & 2nd Sacral Nerves.	Serves to draw pelvis forward; and assists in steadying it upon head of femur.
Obturator internus	Desc. ramus os pubis Ramus of ischium at side & inner surf. Innom. bone below & behind pelvic brim, from upper part Gr. Sacro-sciatic foramen above and behind to thyroid foramen	Leaves pelvis by lesser sacro-sciatic foramen; Inserted into fore part of inner surface of great trochanter in front of Obturator externus	5th Lumbar & 1st & 2nd Sacral Nerves.	Outward rotators of thigh. Also draw pelvis forward when femur is

Gracilis	Lower ½ margin symp. & ant ½ of pubic arch.	upper shaft of inner surf. shaft of tibia, below the tuberosity.	3rd & 4th Lumbar thro Obturator Nerve.	flexor & inward rotator of leg, also an adductor of thigh
Adductor magnus	Small part desc. ramus pubis, ramus of isch.; outer margin inf. part tub. isch.	Rough l. from Gr. troch. to lin. asp. Linea aspera adductor tubercle on inner cond. of femur	" (also a branch from sacral plexus thro Gr. sciatic)	Adduct thigh.
Adductor longus.	Front of os pubis	Linea aspera (between Vast. int. and Add. mag).	3rd & 4th Lumbar, thro Obt. nerve.	" (assists in flexing thigh upon pelvis).
Adductor brevis.	Outer surf. of body & desc. ramus os pubis (between gracilis & Obt. ext.).	Lower part of l. from l. troch. to linea aspera & upper part of same line	"	"
Posterior Femoral Region (Hamstring muscles) Biceps	Arises by 2 heads. Long head - back part tuber. ischium (com. tend. with Semi-T.) & lower part of Gr. Gr. Sacro-sci. lig. Short head - outer lip linea aspera, from outer prol. of l. asp. & within 2 in. of Outer Condyle, and from Ext. Intermusc. Sept.	Outer side of head of fibula & by a small slip to lateral surf. Ext. tub. of tibia	1st, 2nd, & 3rd Sacral, thro Gr. Sciatic Nerve.	Flex leg on thigh. Also rotates leg sl. outward
Semitendinosus	Lower & inner portion tuberosity of ischium (com. tend. with Biceps)	Upper portion of inner surface of shaft of tibia	"	Flex leg on thigh Also rotates leg inward.
Semi membranosus	Upper & back portion of tuberosity of ischium.	Groove on inner and back part inner tuberosity of the tibia.	"	"

Muscles-	Origin-	Insertion-	Nerve-Supply-	Action
Vastus externus-	Apon. from upper ½ Ant. Inter-trochanteric line; outer lip gluteal ridge; upper ½ outer lip of linea aspera	Outer border of patella, blending with gr. Ext. tendon	2nd, 3rd, & 4th Lumbar Nerves, thro. br. of Ant. Crural	Extends leg upon thigh
Vastus internus=	Lower ½ ant. inter-trochanteric line; spiral line; inner lip linea aspera; upper part int. supra-Condylar line; & tend. of add. magnus & int. intermusc. septum	Inner border of patella & Quad. Ext. tend.	"	" (Also draws patella inward).
Vastus medius (Crureus).	Front and outer aspect of shaft of femur in its upper ⅔. & from lower part ext. intermuscular septum.	Patella - its aponeurosis forms deep part of the Quadriceps Extensor tendon.	"	Extends leg upon thigh.
Subcrureus-	Ant. surf. lower part of shaft of femur	Upper part of cul-de-sac of capsular lig. which projects upward beneath Quadriceps.	"	"

Internal Femoral Region

Muscles-	Origin-	Insertion-	Nerve-Supply-	Action
Pectineus-	Linea ilio-pectinea & to a slight extent from surf. of bone in front of its ilio-pect. emin. & spine of os pubis, & from fascia covering the ant. surf. of the muscle	Inserted into a rough line leading from lesser trochanter to linea aspera.	"	Adducts thigh. Rotates thigh outwards. Assist in flexing thigh upon

Deep fascia = fascia lata. Attached above and behind to back of sacrum and coccyx; externally to crest of ilium; in front to Poupart's lig. and body os pubis. internally to desc. ramus os pubis & tub. of isch. and lower bord. gr. sacro-sciatic lig. Splits to surround Gluteus maximus. Reunites below G. max. Below-attached to all prominent points around knee joint — Cond. femur, tub. of tibia, & head of fibula.

Saphenous opening — at upper & inner part of thigh — transmits int. saphenous vein. etc.

Iliac portion — all on outer side of saphenous opening.

Pubic portion — at inner side of saph. open. Covers Pectineus Add. longus, & Gracilis M. is contin. with sheath of Ilio-psoas, and attached to ilio pectineal line.

Sartorius	Ant. Sup. Spinous process Ilium and upper half of notch below it.	Upper part of the inner surface of shaft of tibia nearly as far forw. as the crest.	2nd, 3rd & 4th lumbar nerves, through branches of ant. crural.	Flexes leg upon thigh, flexes thigh upon pelvis, next rot. thigh outw.
Quadriceps Extensor =	(Includes 4 muscles) — on front of thigh.		" (2, 3, & 4 L. thro. ant. crural.	Extends the leg upon the thigh.
Rectus femoris —	Arises by 2 tendons — Ant. or Str. — from ant. inf. sp. pr. Ilium. Post. or Refl. t. — from groove above brim of acetabulum.	Aponeurosis oc. lower $\frac{2}{3}$, tendon inserted into patella. Lig. patellae extends down to tuberosity of tibia.		

Muscles -	Origin -	Insertion	Nerve-Supply	Action
Iliac Region -				
Ilio-psoas				
Iliacus	upper 2/3 iliac fossa & inner margin crest of ilium, Ilio-lumbar lig. & base of sacrum, front ~~notch~~ betw. them, and by a few fibres from capsule of hip joint	outer side of tend. of Psoas, to shaft of femur about 1 inch below and in front of lesser trochanter.	Ant. br's. 2nd & 3rd lumbar nerves thro Ant. Crural	Acting from above, flex thigh upon pelvis. From below bend spine & pelvis forward. Maintain Erect position. Raise trunk when body is recumbent
Psoas magnus	Front of bases and lower borders bases transv. proc. of lumbar vertebrae also sides of bodies of last dorsal and all 5 lumbar V.	Passes across brim of pelvis, terminates in a tendon which (receives nearly all fibres of Iliacus) is inserted into lesser trochanter of femur	Ant. br. 2nd & 3rd lumbar nerves.	
Psoas parvus	Sides of bodies of last dorsal and 1st lumbar vert. & intervertebral subst. betw. them.	Ilio-pectineal eminence, and iliac fascia. Often absent.	Ant. br. 1st lumbar nerve.	Tensor of iliac fascia.
Anterior Femoral Region -				
Tensor fasciae femoris	Ant. part outer lip crest of ilium & outer surf. sup. sp. proc, and part of outer border of notch below it & surf. of fasc. glut. med.	Inserted betw. 2 layers of fascia lata, about 1/4 down outer side of thigh. From point of insertion cont. downward to ext. tuberosity of tibia as Ilio-tibial band	4th & 5th lumbar & 1st sacral through Superior Gluteal Nerve.	Tensor of fascia lata. Also abducts and rotates thigh inward

Superficial fascia

Superf. layer cont. with superf. fascia of abd.

Deep layer - beneath superf. layer and upon fascia lata. Portion covering saphenous opening - Cribriform fascia

Transversalis	Fleshy fibres from outer $\frac{1}{3}$ Poupart's Lig. - from inner lip of crest ilium for its ant. $\frac{3}{4}$; from inner surface Carts. 6 lower ribs. from lumbar fascia	Broad aponeurosis inserted together with Int. Obl. in lower part of linea alba, crest of os pubis and pectineal line. Upper $\frac{3}{4}$ passes behind Rectus muscle. Lower $\frac{1}{4}$ in front of Rectus.	Same as Internal Oblique	Same as Ext. Oblique
Rectus abdominis.	Arises by two tendons - External one from crest of os pubis Internal one interlacing with fellow of opposite side, connected with ligaments covering front of symphysis pubis	By three portions of unequal size into cartilages of 5th, 6th & 7th ribs. Occasionally a few fibres to costo-xiphoid ligaments and side of the ensiform Cart.	Same as Ext. Obl. Lower Intercostal nerves	Same as Ext. Oblique

Crossed by 3 lineae transversae
Enclosed in sheath formed by the aponeuroses of Int. Obl. and Transversalis

Pyramidalis	Small, triangular By tendinous fibres from front of os pubis and Ant. pubic lig	Linea alba midway between umbilicus & os pubis. Sometimes wanting on one or both sides	~~Same~~ Inter-costal nerves	

Muscles	Origin.	Insertion.	Nerve-Supply.	Action.
Obliquus internus Internal or Ascending Oblique	By fleshy fibres, from outer ½ of Poupart's lig.; Ant. ⅔ middle lip crest of ilium, and posterior lamella of lumbar fascia. Fibres diverge.	Fibres from P.'s lig. inserted conjointly with those of Transversalis into crest of Os pubis & pectineal line. From ant. ⅓ of iliac origin are horizontal – into linea alba. From mid. ½ of crest of ilium, divides into 2 lamellae, which pass in front & behind Rectus M. to linea alba. Posterior lamella also to cart. of 7th 8th 9th ribs. The most posterior fibres pass upward to cartil. of 3 lower ribs, continuous with Int. Intercostal Muscles	Lower Inter-costal Nerves. Also by filaments from Hypogastric branch of Ilio-hypogastric & sometimes from the Ilio-Inguinal	Same as Ext. Oblique

Semilunar fold of Douglas – a deficiency in sheath of Rectus Muscle behind, where apon. of Int. Oblique ceases to split, and passes in front.

Conjoined Tendon – of Int. Oblique and Transversalis Muscles –
Inner portion = Ligament of Hesselbach
Outer " – " " Henle

Muscles	Origin.	Insertion.	Nerve-Supply.	Action.
Cremaster –	fasciculi from inner part of Poupart's Ligament	Pass down along spermatic cord and testes and ... to	~~Genital branch~~	

Muscles	Origin	Insertion	Nerve-Supply	Action
~~(Abdomen—Superficial Layer)~~				
Obliquus externus (Descending Oblique)	By 8 fleshy digitations from ext. surf. & lower border of 8 inferior ribs. 5 super. insertions between proc. of Serratus magnus 3 lower ones betw. Latissimus dorsi	Fibres from lower ribs into ant. ½ outer lip of crest of ilium Middle & lower fibres in aponeurosis opp. line drawn from prominence of 9th Cost. cart. to Ant. sp. proc. of ilium	Lower Inter-costal Nerves.	3-fold. When pelvis & thorax are fixed, compr. abd. viscera Pelvis & spine fixed, comp. lower thorax. Thorax fixed, draw pelvis upward.

Aponeurosis of External Oblique – directed oblig. downward and inward. Fuses with opp. muscle along median line forming Linea alba. Covers whole of front of abdomen. Fibres closely aggregated together below.

Poupart's ligament – portion from Ant. sup. spine of ilium to spine of Os pubis

Gimbernat's ligament – portion reflected from P.'s lig. at spine of os pubis along pectineal line.

Triangular fascia of abdomen – a few fibres passing upward and inward from attachment of G.'s L. to pectineal line – to the linea alba.

External Abdominal ring – a triangular opening in aponeurosis immediately above crest of the os pubis.

Intercolumnar fibres – pass across lower part of aponeurosis.

Ligament of Cooper – from base of G.'s lig. along ilio-pectineal line.

University Book Store,
CERNY & LOUIS,
BOOKS & STATIONERY,
Iowa City, Iowa.